

DIDACTIC IMAGE

AXENFELD'S ANOMALY

COPPENS G*, ZEYEN T*

A mother with congenital glaucoma, secondary to Axenfeld-Rieger syndrome visited us with her first baby. An examination under general anesthesia showed a prominent, anteriorly displaced Schwalbe's line (often referred to as posterior embryotoxon), a clear cornea and an atro-

phic iris without corectopia (Fig 1). We saw a normal corneal diameter and asymmetrical cupping of the optic discs; cup/disc ratio of 0.7 in the right eye (Fig 2) and 0.5 in the left eye (Fig 3). The intraocular pressure was 11 mmHg in both eyes. Gonioscopic examination revealed iridocorneal adhesions (much more prominent than physiological processus irides), bridging the anterior chamber angle from the peripheral iris to the prominent Schwalbe's ridge; beyond the tissue strands, the angle was open (Fig 4).

.....

* Department of ophthalmology, University Hospitals, Leuven, B-3000, Belgium

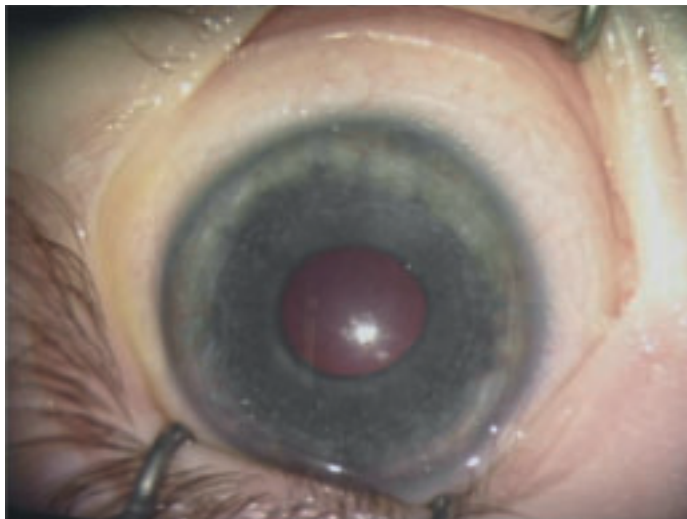

Fig. 1




Fig. 4

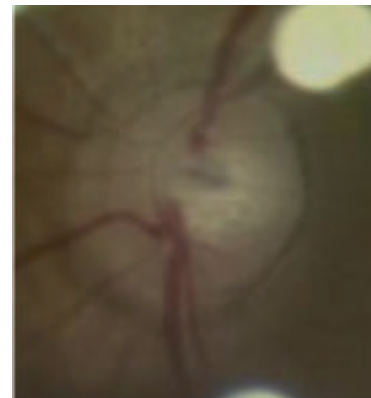


Fig. 2

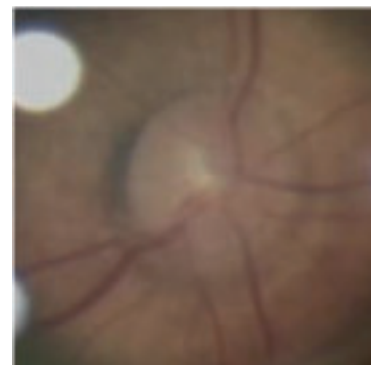


Fig. 3

Traditionally, this condition has been designated as Axenfeld's anomaly. Rieger's anomaly involves changes in the iris (iris atrophy with corectopia and/or polycoria), and Rieger's syndrome is associated with systemic developmental defects. The mode of inheritance is autosomal dominant. Half of the patients with Axenfeld-Rieger syndrome can develop glaucoma (1).

REFERENCE

- (1) SHIELDS M.B., BUCKLEY E., KLINTWORTH G.K., THRESHER R. – Axenfeld-Rieger syndrome. A spectrum of developmental disorders. *Surv Ophthalmol.* 1985; 29: 387-409.