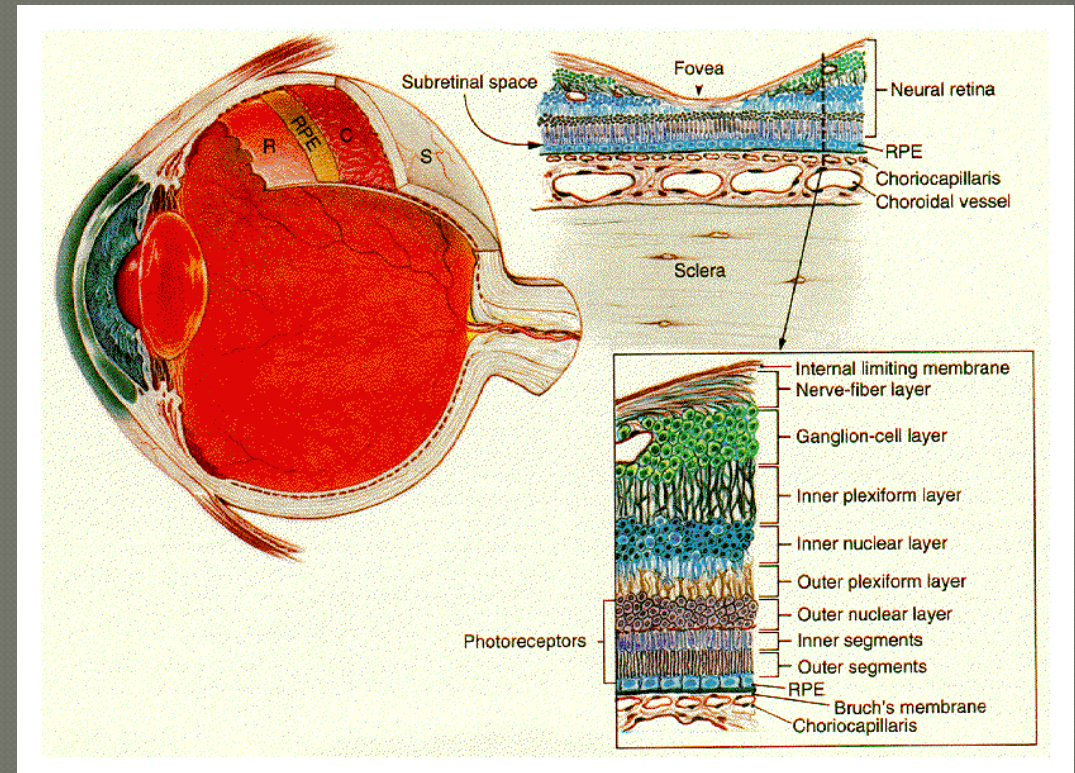


Uveites

Laure Caspers

Definition and Epidemiologie

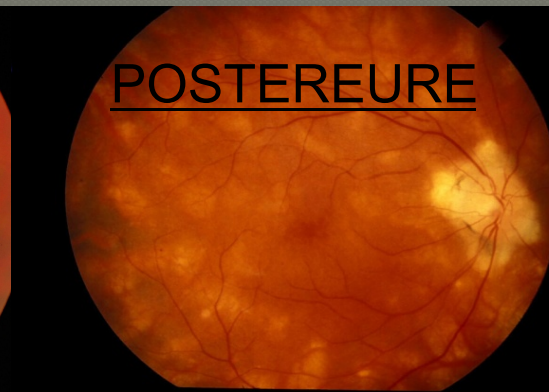
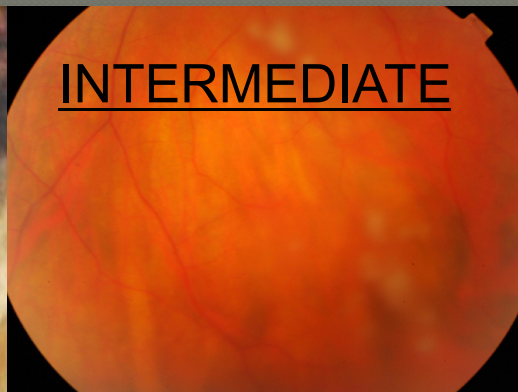
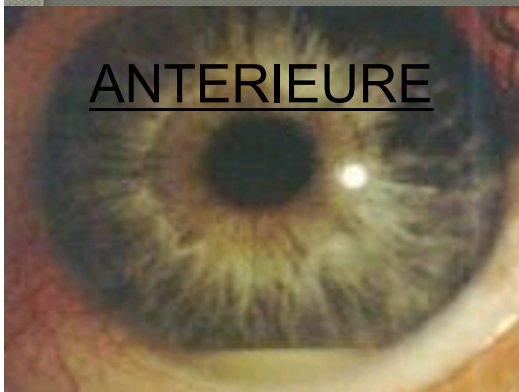- Uvée =
Iris, Corps ciliaire Choroïde
- Uvéite = Inflammation
dans l'uvée
« Inflammation intraoculaire »
(+rétine)
- Différentes classifications



Definition and Epidemiology

- Différentes classifications

1/ Anatomique



PANUVEITIS

Ant → Post

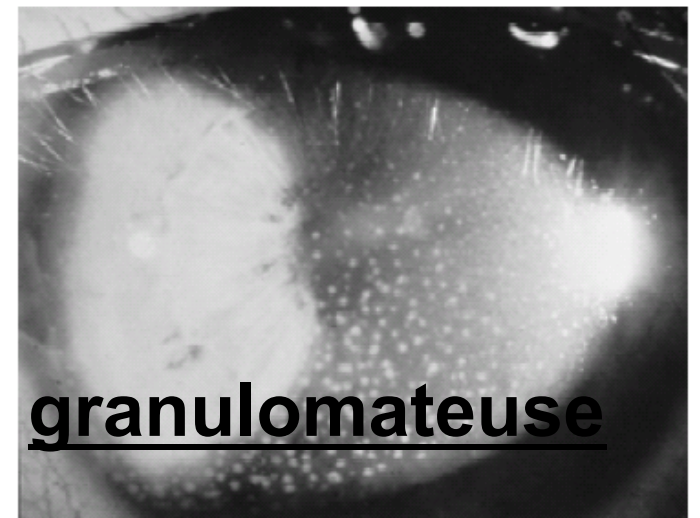2/ non granulomateuse
versus /granulomateuse

3/ Mécanisme

Infectieux

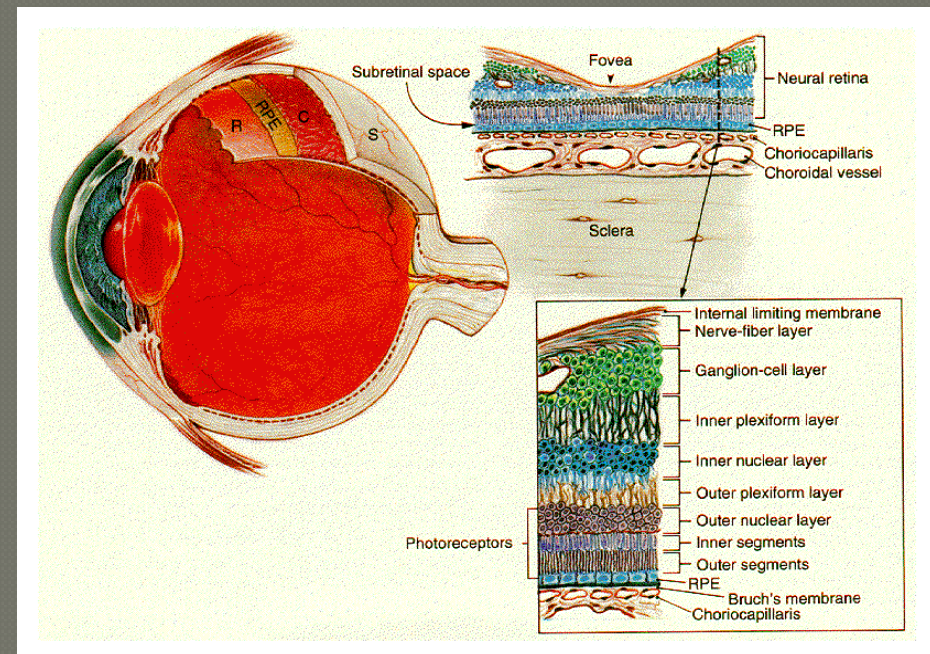
Non Infectieux =

Autoimmune



classification

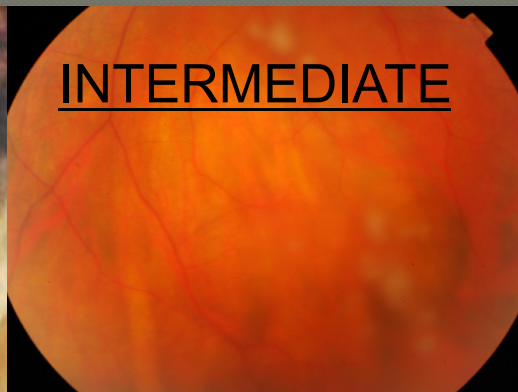
- Antérieures
- Intermédiaires
- Postérieures
- Panuvéites



Definition and Epidemiology

○ Différentes classifications

1/ Anatomique



PANUVEITIS

Ant → Post

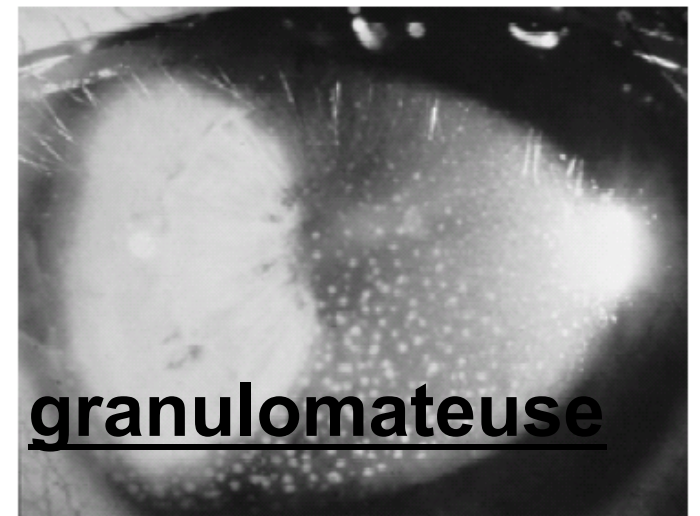2/ non granulomateuse versus /granulomateuse

3/ Mécanisme

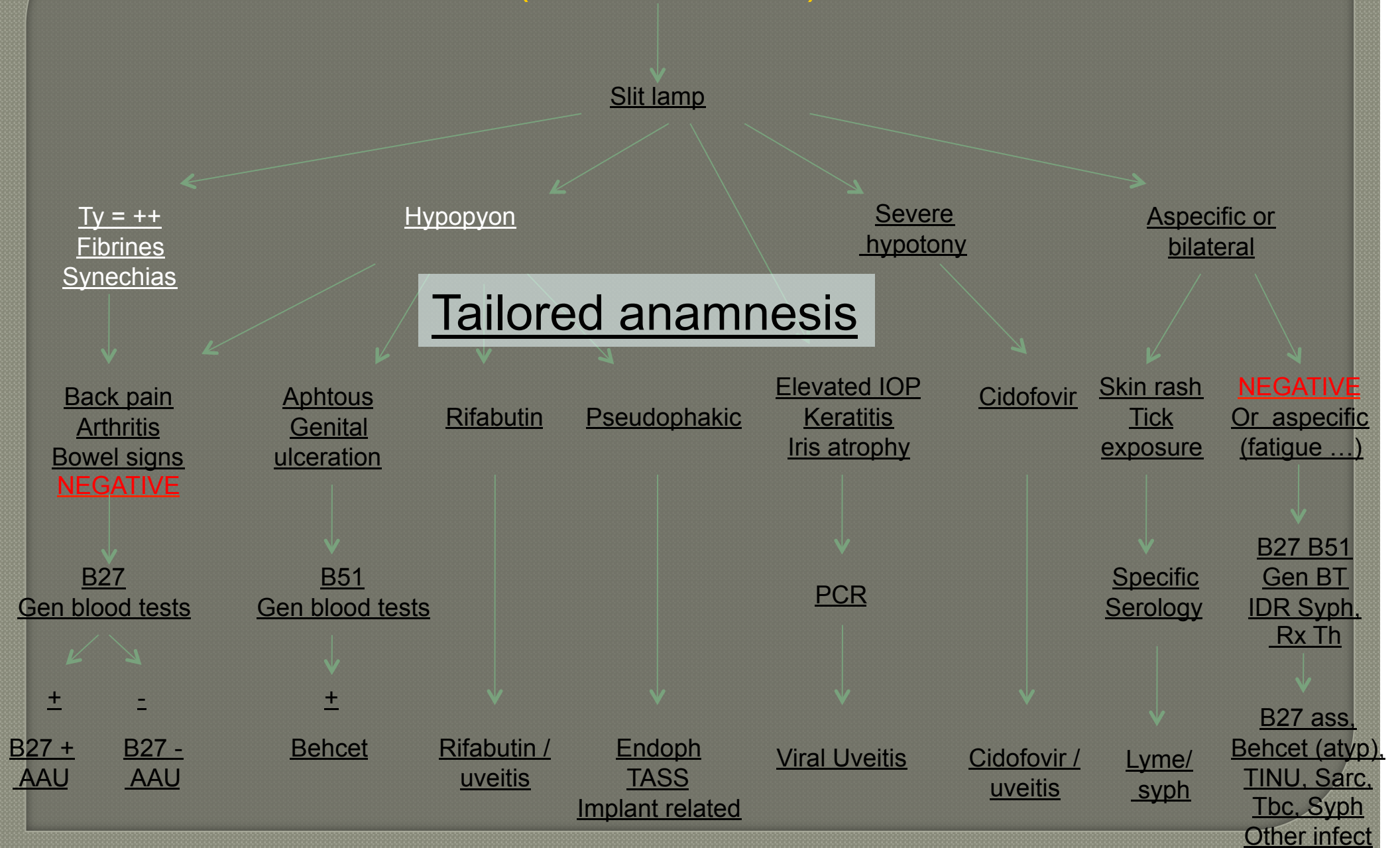
Infectieux

Non Infectieux =

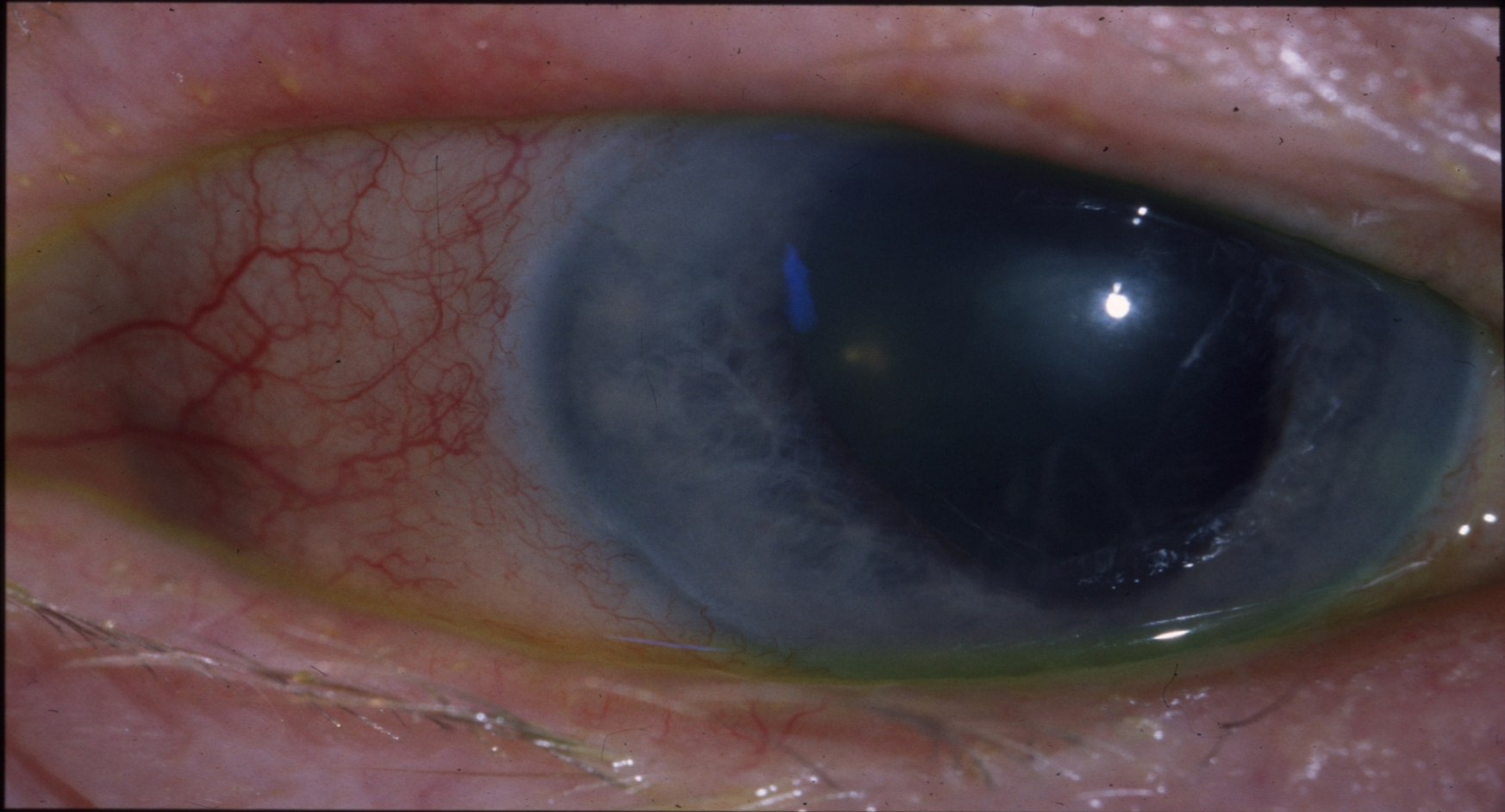
Autoimmune

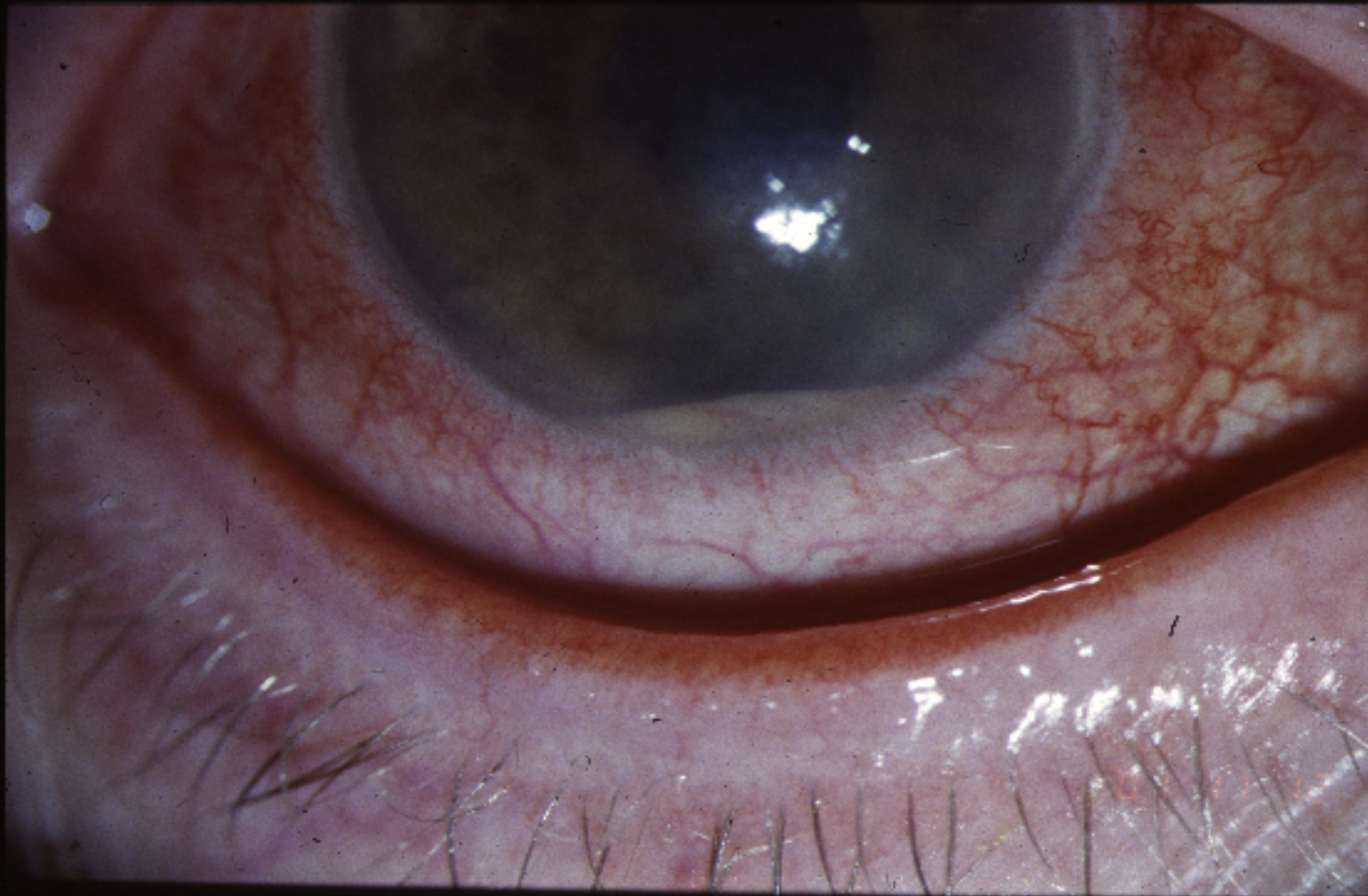


Anterior Uveitis : Non Granulomatous (Normal fundus)

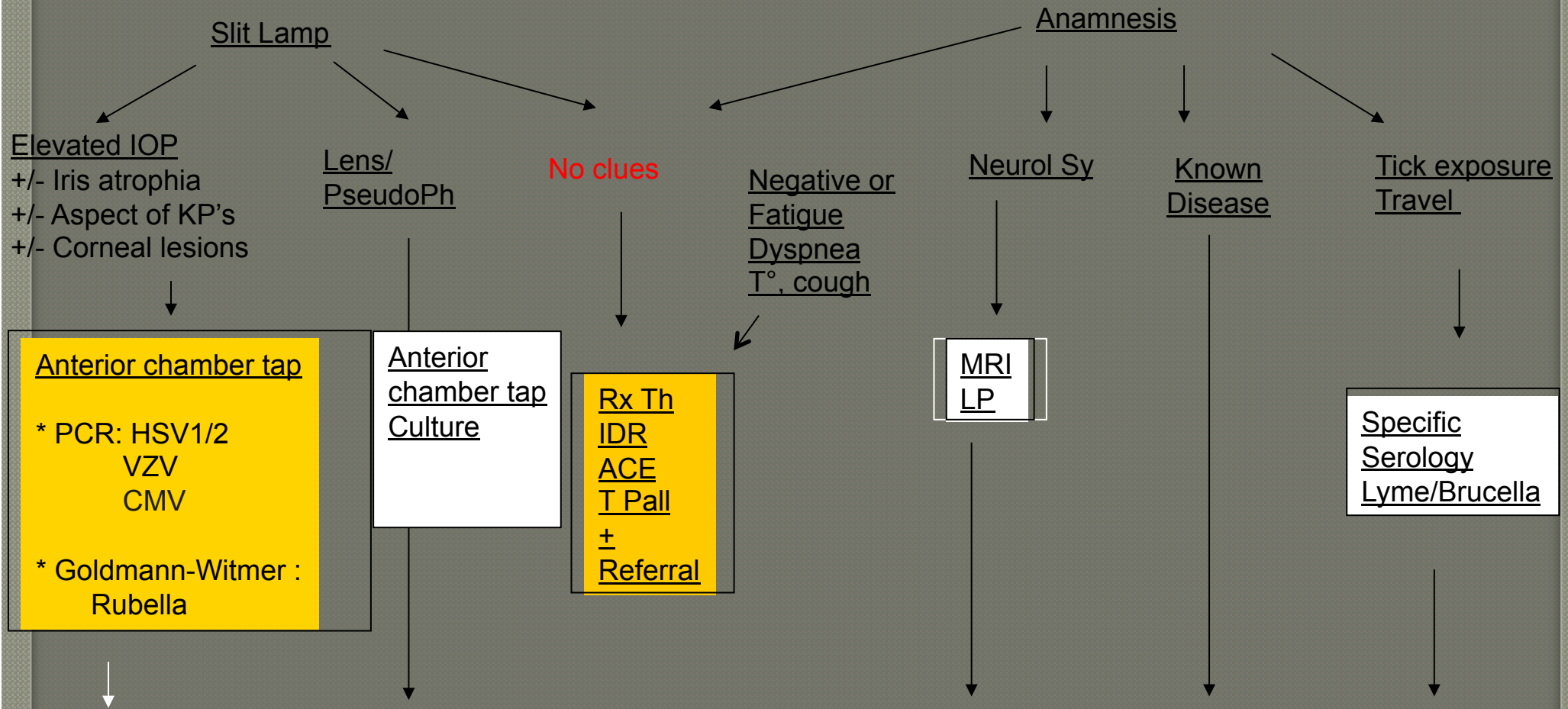


Classification: uvéite non granulomateuse





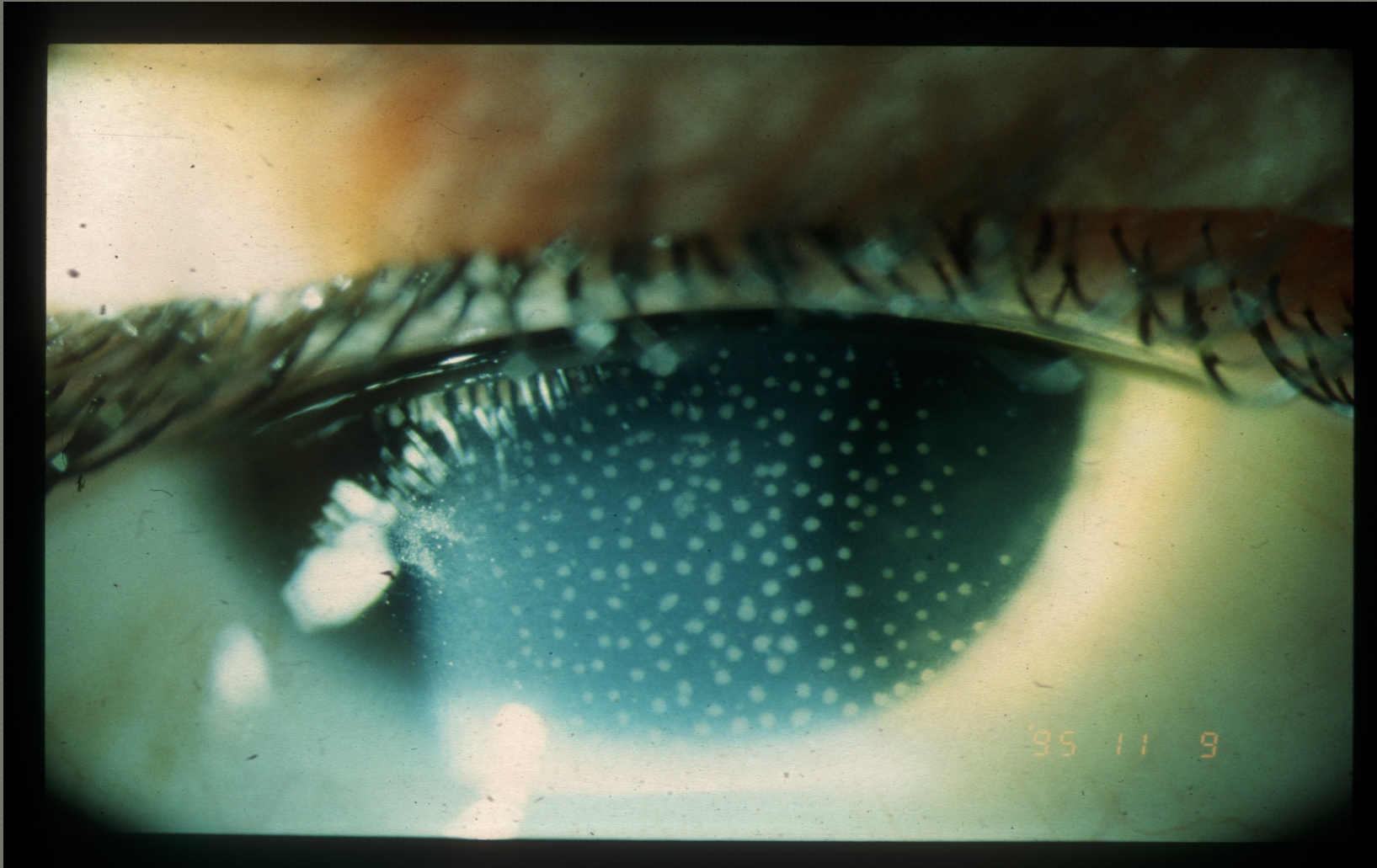
Anterior granulomatous uveitis (Normal fundus)



Diagnosis

Viral / Fuchs / Lens-induced / Chronic Endoph / MS / VKH / Sarc / Tbc / Syphillis / Lyme / Brucella ...

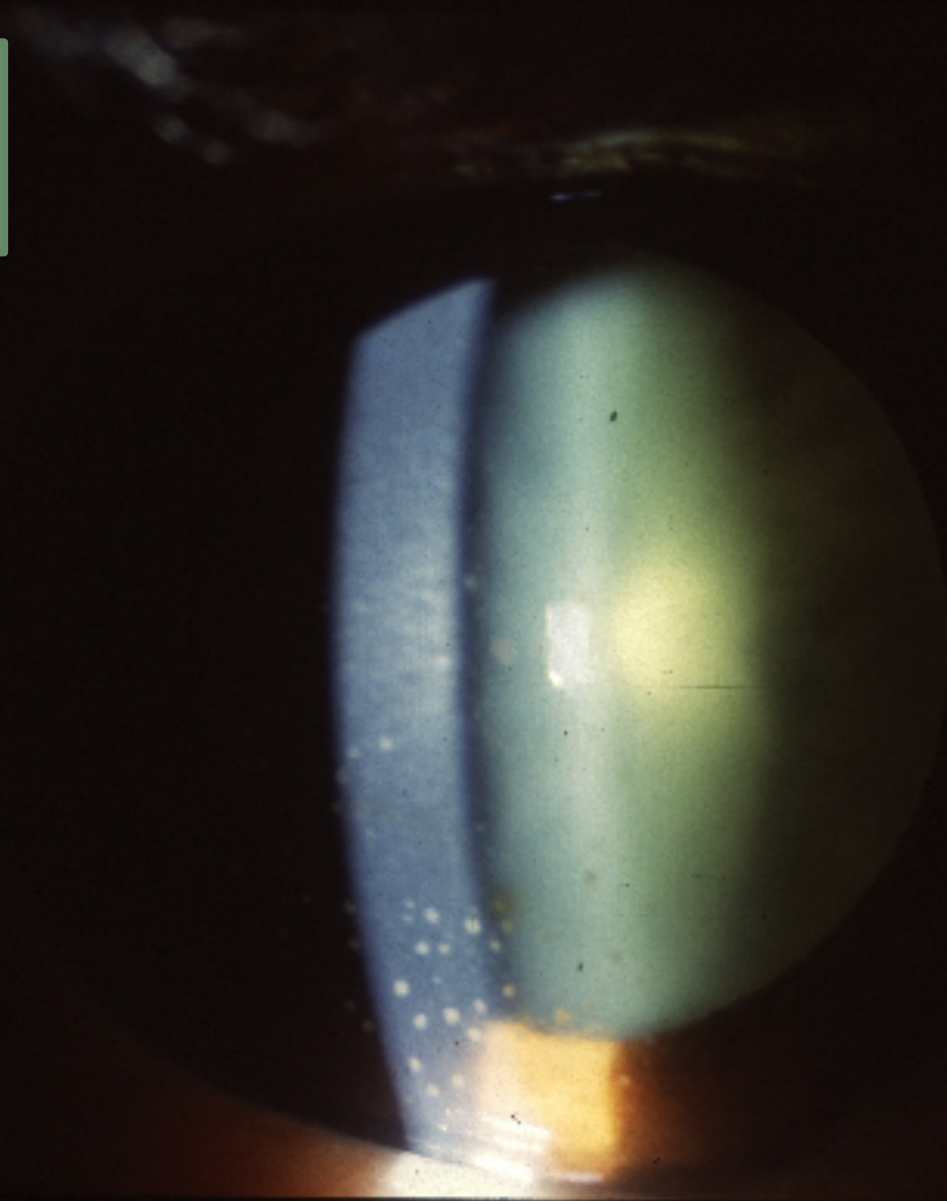
Classification: uvéite granulomateuse





Tuberculose

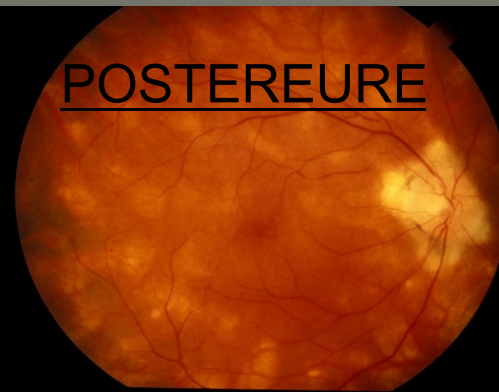
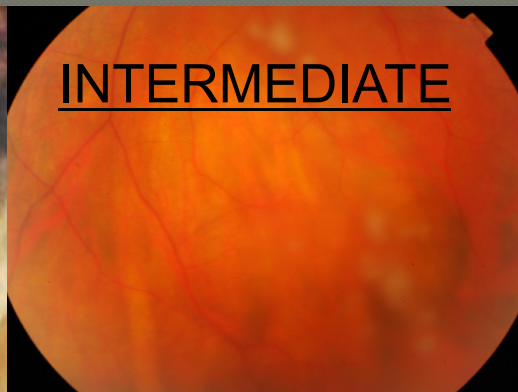
CMV



Definition and Epidemiology

○ Différentes classifications

1/ Anatomique



PANUVEITIS

Ant → Post

2/ non granulomateuse
versus /granulomateuse

3/ Mécanisme

Infectieux

Non Infectieux =

Autoimmune



Uvéites

Histoire clinique

Examen clinique

Diagnostic différentiel

1 test – 1 mise au point complète

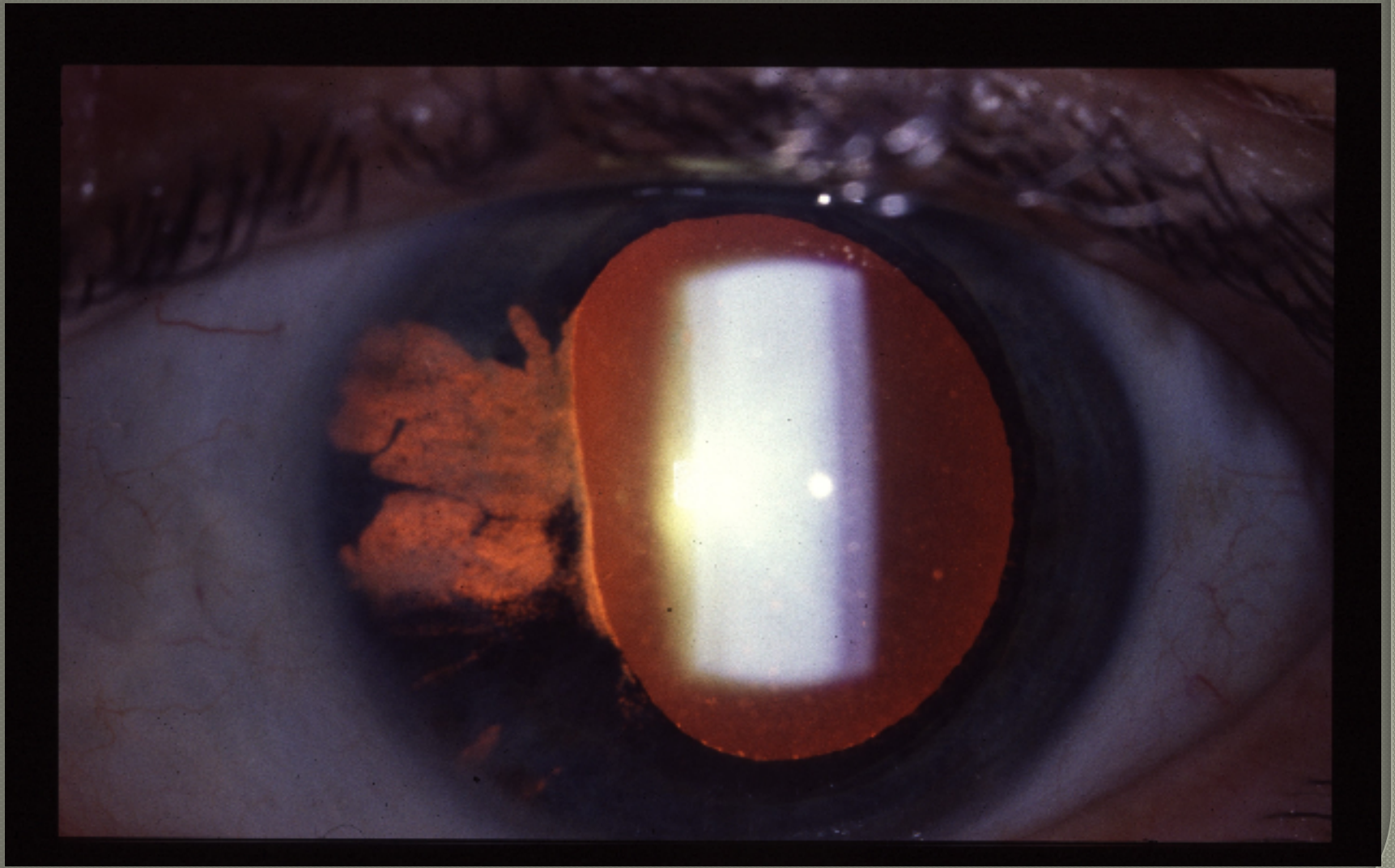
Maladie infectieuse spécifique

Traitement Spécifique

Maladie autoimmune disorder

immunosuppression

Idiopathique



Definition and Epidémiologie : Etiologies

Infectieux

Herpes

Fuchs

Posner-Scholsman

Lyme

Tbc

Syphillis

Toxoplasmosis

Toxocara

...

Non infectieux,

Idiopathique

Sarcoidose

MS

Behcet

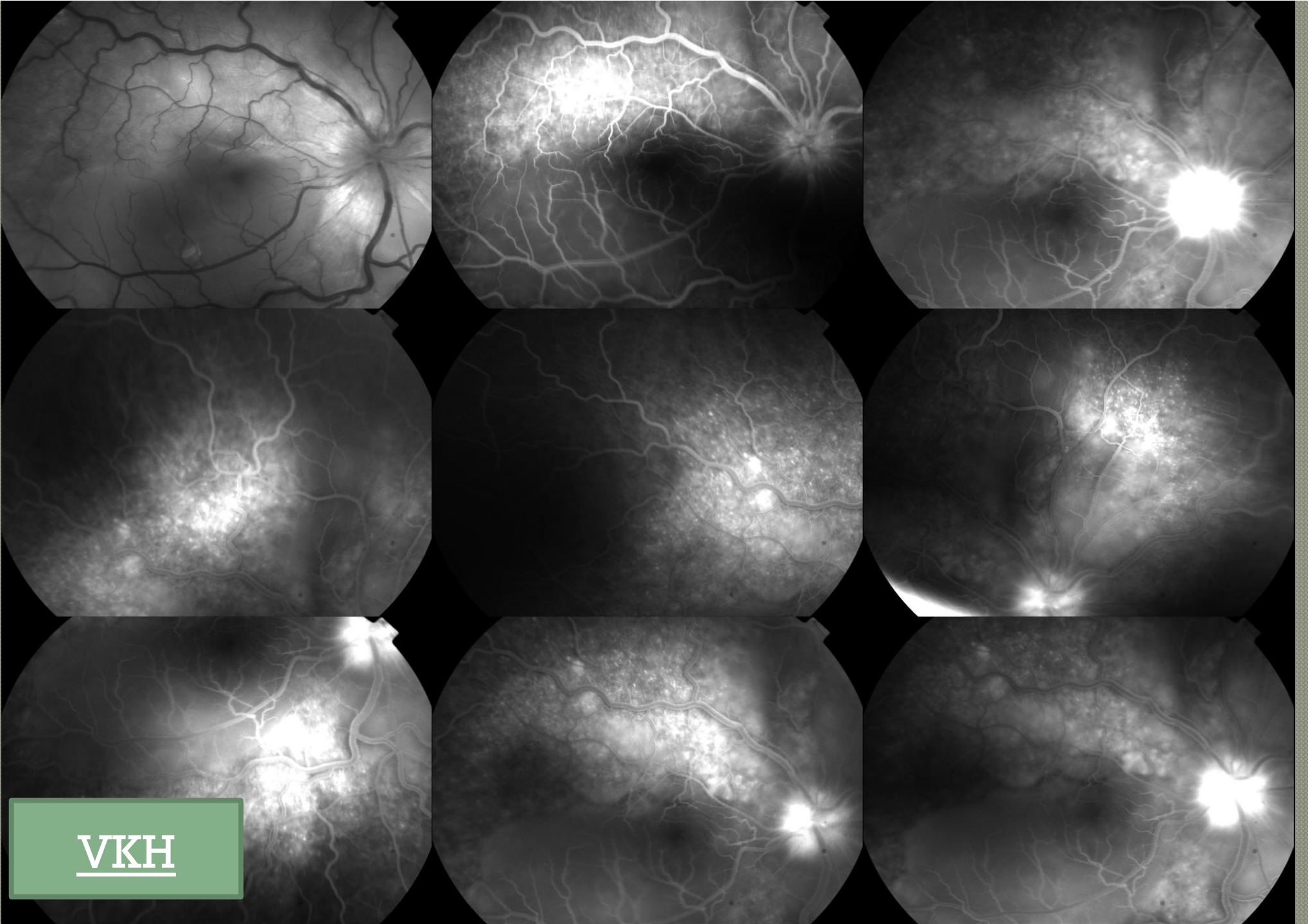
Birdshot

serpigneuses

VKH

Opht symp

...



VKH

Definition and Epidémiologie :

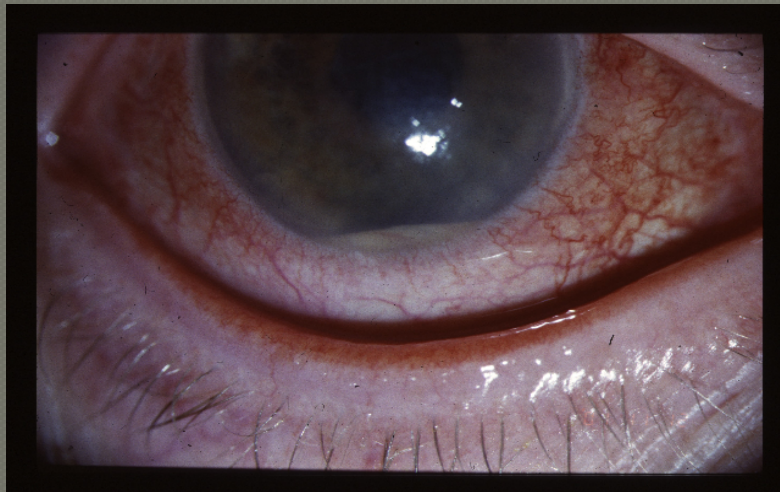
aigüe

HLA B 27, SPA

Herpes

Toxoplasmosis

Behcet



chronique

Fuchs

Intermédiaire

idiopathique

Sarcoidose

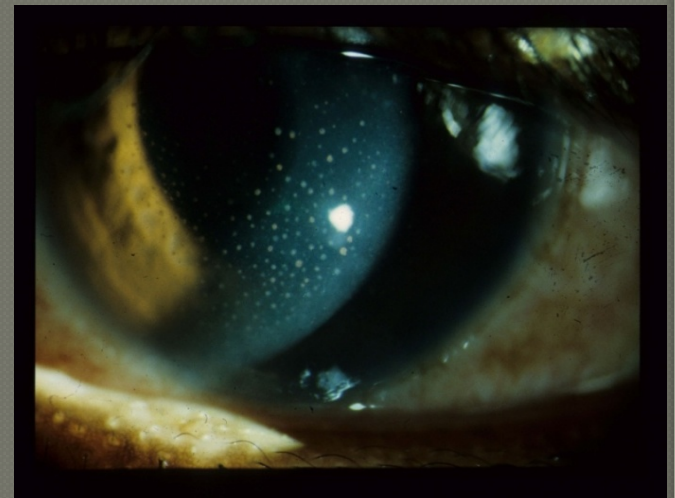
MS

Birdshot

VKH

Opht symp

...



Definition and Epidémiologie : Etiologies

Antérieure

Idiopathique

HLA-B27 associated

Sarcoidose

Herpes

Fuchs

Posner-Scholsman

Lyme

Tbc

Syphillis

Mascarade

...

Intermédiaire

Idiopathique

Sarcoidose

MS

Syphillis

Tbc

...

Post

Toxoplasmosis

Idiopathique

Sarcoidose

Behcet

Herpes

Syphillis

Tbc

Lyme

Toxocara

Birdshot

W D syndrome

Panuvéite

Toxoplasmosis

Idiopathique

Sarcoidose

Behcet

Herpes

Syphillis

Tbc

VKH

Opht symp

...

Uvéite Antérieure Aigüe Autoimmune

30 / 50 % HLA B27 +

50 / 70 % HLA B27 -

20/50 % Association
Art Sero -

50/70% Pas d'Association
Art Sero -

Sero – A rarement retrouvé

Spondylarthrite Ankylosante 55 %

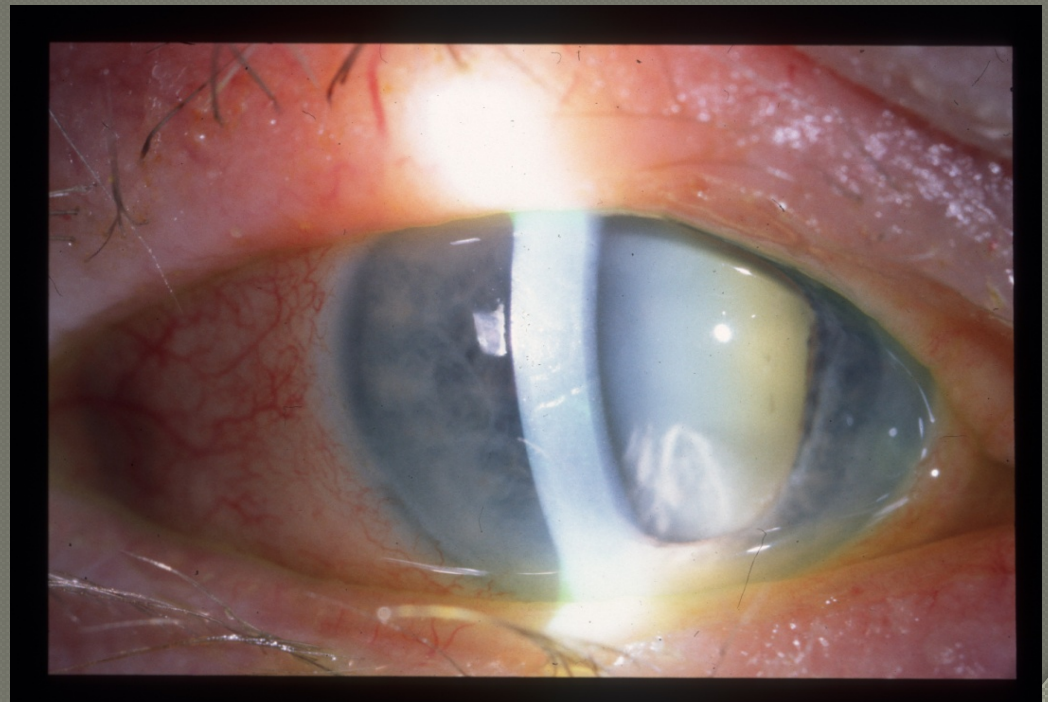
Syndrome de Reiter 25 %

Arthrite Psoriasique 10 %

IBD 10 %

Uvéite antérieure aigüe

- La plus fréquente 50 %
- Histoire d'autres épisodes d'uvéite
- Histoire de douleurs dans le bas du dos (SPA)
- Histoire familiale d'uvéite ou D+ dos



Definition and Epidémiologie : Etiologies

Antérieure

Idiopathique

HLA-B27 associated

Sarcoidose

Herpes

Fuchs

Posner-Scholsman

Lyme

Tbc

Syphillis

Mascarade

...

Intermédiaire

Idiopathique

Sarcoidose

MS

Syphillis

Tbc

...

Post

Toxoplasmosis

Idiopathique

Sarcoidose

Behcet

Herpes

Syphillis

Tbc

Lyme

Toxocara

Birdshot

W D syndrome

Panuvéite

Toxoplasmosis

Idiopathique

Sarcoidose

Behcet

Herpes

Syphillis

Tbc

VKH

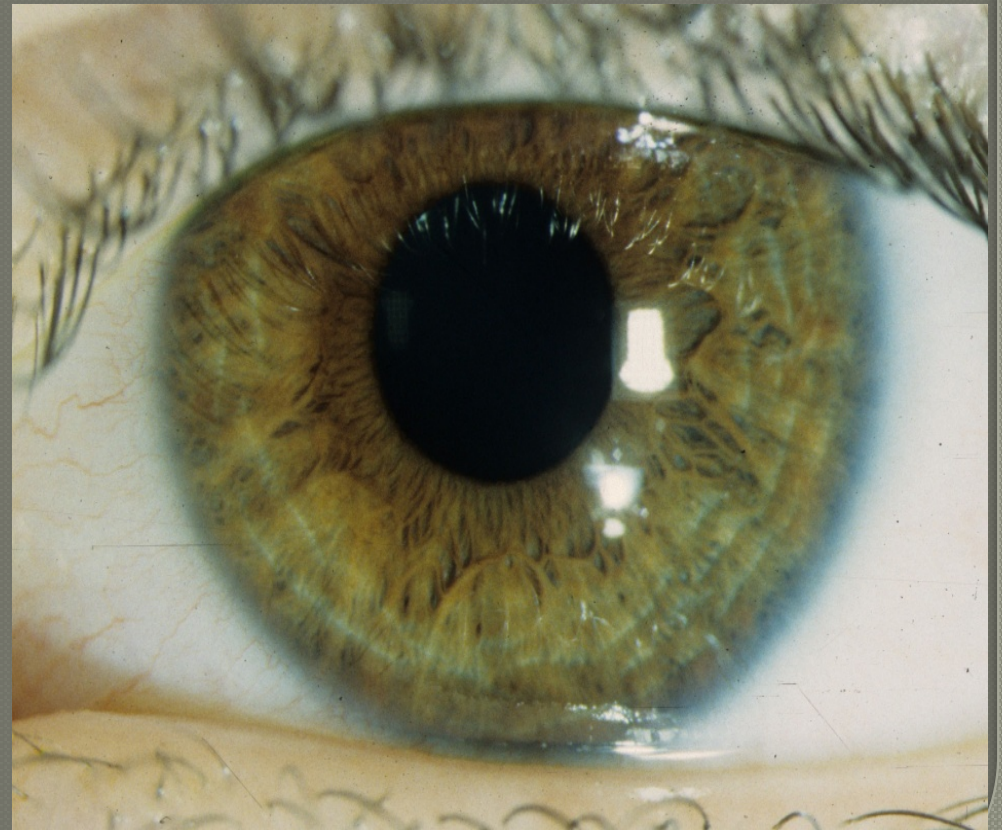
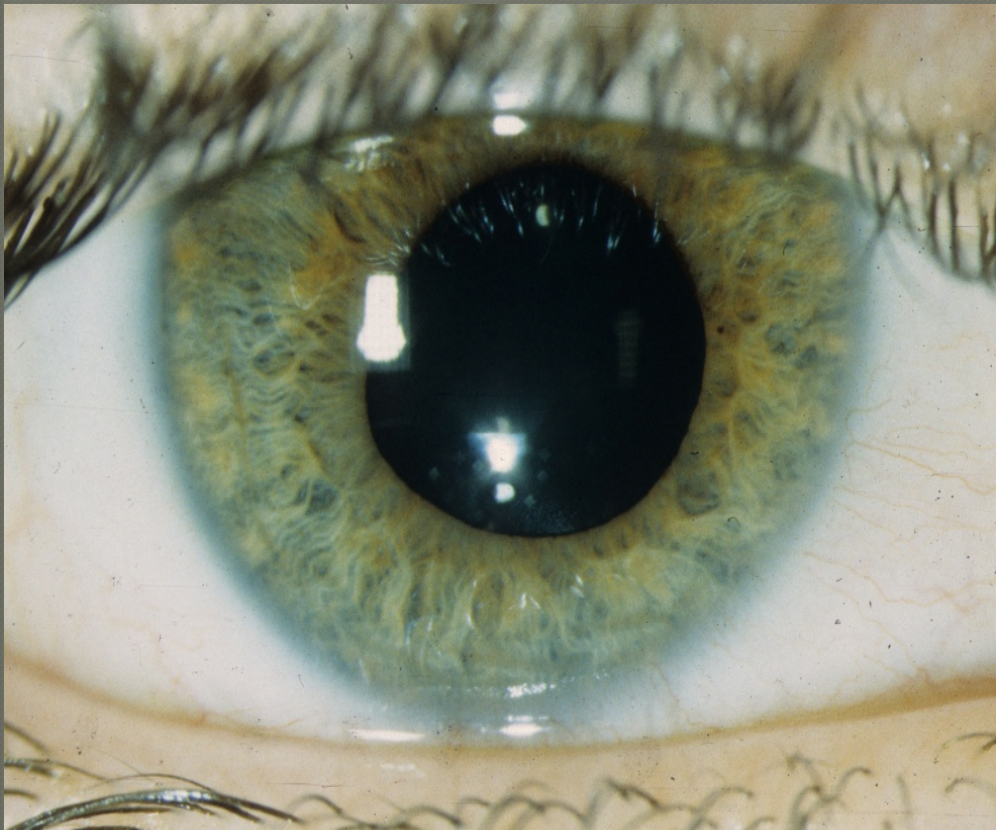
Opht symp

...

Hétérochromie

COULEUR DÉLAVÉE

COULEUR NORMALE



Definition and Epidémiologie : Etiologies

Antérieure

Idiopathique

HLA-B27 associated

Sarcoidose

Herpes

Fuchs

Posner-Scholsman

Lyme

Tbc

Syphillis

Mascarade

...

Intermédiaire

Idiopathique

Sarcoidose

MS

Syphillis

Tbc

...

Post

Toxoplasmosis

Idiopathique

Sarcoidose

Behcet

Herpes

Syphillis

Tbc

Lyme

Toxocara

Birdshot

W D syndrome

Panuvéite

Toxoplasmosis

Idiopathique

Sarcoidose

Behcet

Herpes

Syphillis

Tbc

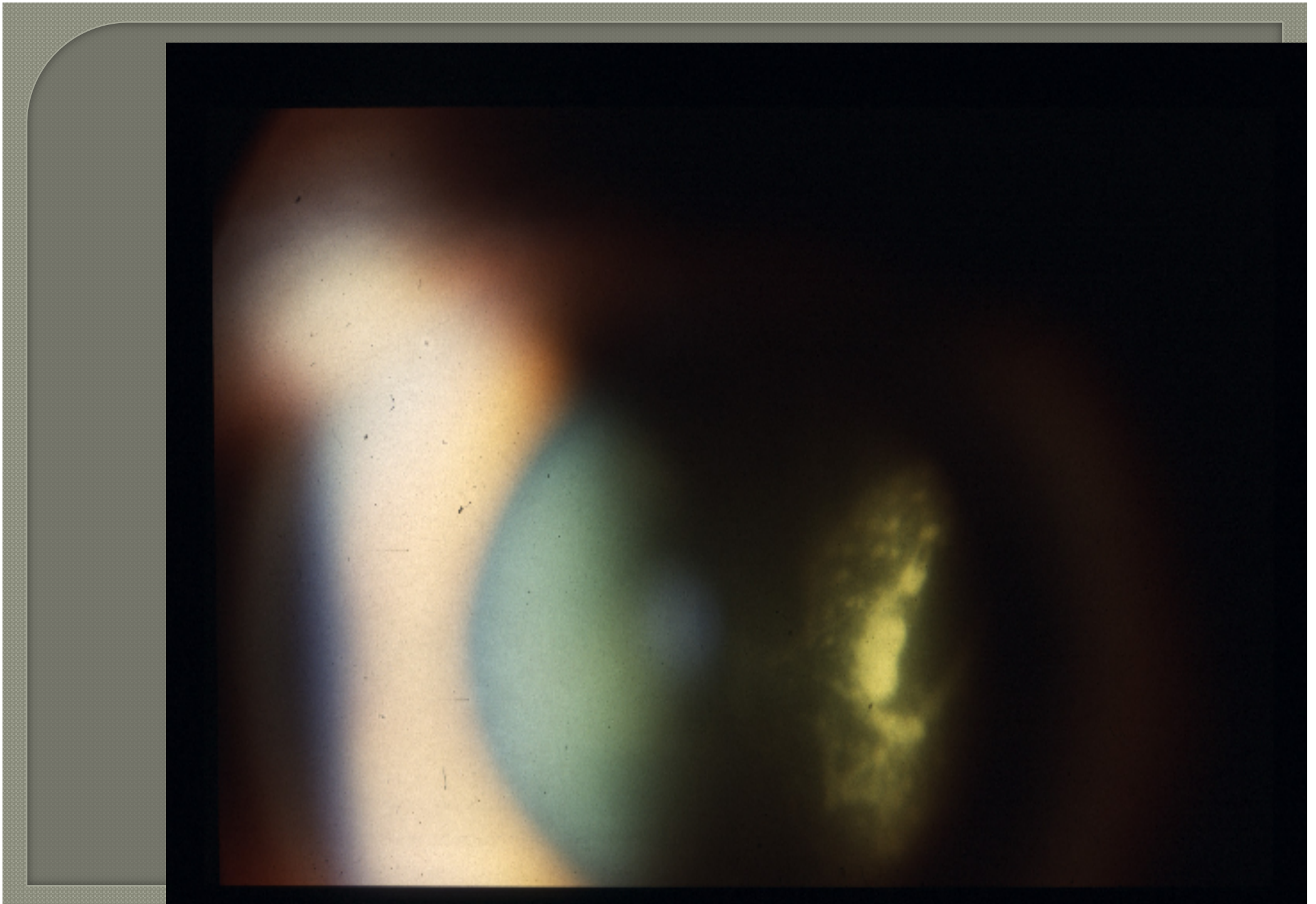
VKH

Opht symp

...

Intermediate Uveitis

<u>Anamnesis</u> <u>Myodésopsies</u>	<u>Slit Lamp</u>	<u>Test</u>	<u>Diagnosis</u>
<u>Young patient</u> <u>Neurol Sy</u>	<u>Granulomatous reaction</u> <u>Periphlebitis</u>	<u>MRI</u> <u>LP</u>	<u>MS</u>
<u>Young Black/</u> <u>Old caucasian</u> <u>Lung problems</u>	<u>Granulomatous reaction</u> <u>Periphlebitis</u> <u>« Tache de bougie »</u>	<u>Rx Th</u> <u>IDR</u> <u>ACE</u>	<u>Sarcoidosis +/- TB</u>
<u>Old Caucasian</u>	<u>Vitritis >>>> VA</u> <u>Neurological problems</u>	<u>MRI</u> <u>LP</u> <u>Vitrectomy</u>	<u>Intraocular lymphoma</u>
<u>Tick bite</u> <u>Rash</u> <u>Arthralgia</u>	<u>?</u>	<u>Specific serology</u>	<u>Lyme</u>
<u>Cat scratch</u>	<u>?</u>	<u>Specific serology</u>	<u>Cat scratch disease</u>
<u>?</u>	<u>?</u>	<u>Rx Th / IDR</u> <u>ACE / T Pall</u>	<u>Sarc / Tbc / Sy</u>



Definition and Epidémiologie : Etiologies

Antérieure

Idiopathique

HLA-B27 associated

Sarcoidose

Herpes

Fuchs

Posner-Scholsman

Lyme

Tbc

Syphillis

Mascarade

...

Intermédiaire

Idiopathique

Sarcoidose

MS

Syphillis

Tbc

...

Postérieure

Toxoplasmosis

CMV

Idiopathique

Sarcoidose

Behcet

Herpes

Syphillis

Tbc

Lyme

Toxocara

Birdshot

Panuvéite

Toxoplasmosis

Idiopathique

Sarcoidose

Behcet

Herpes

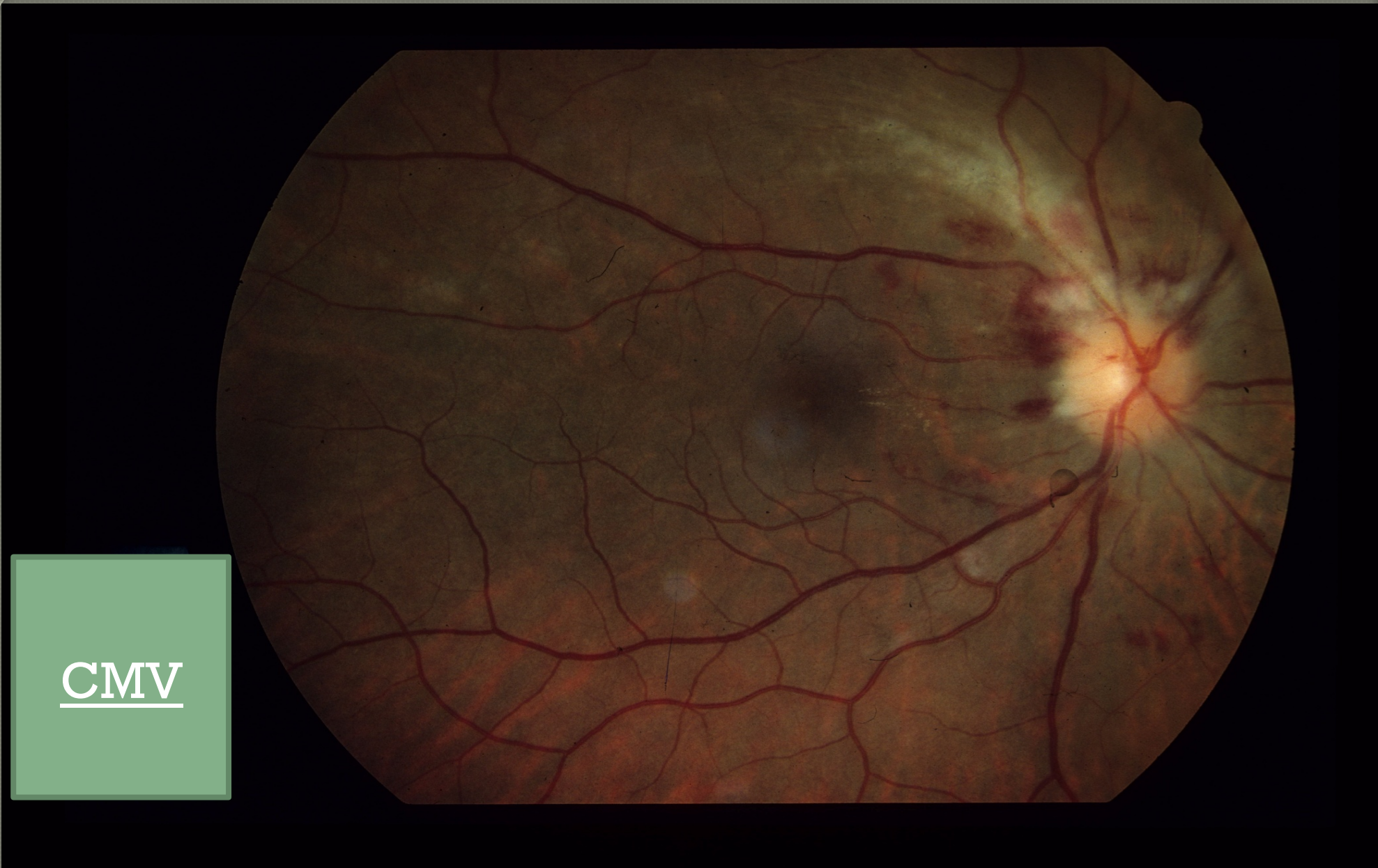Syphillis

Tbc

VKH

Opht symp

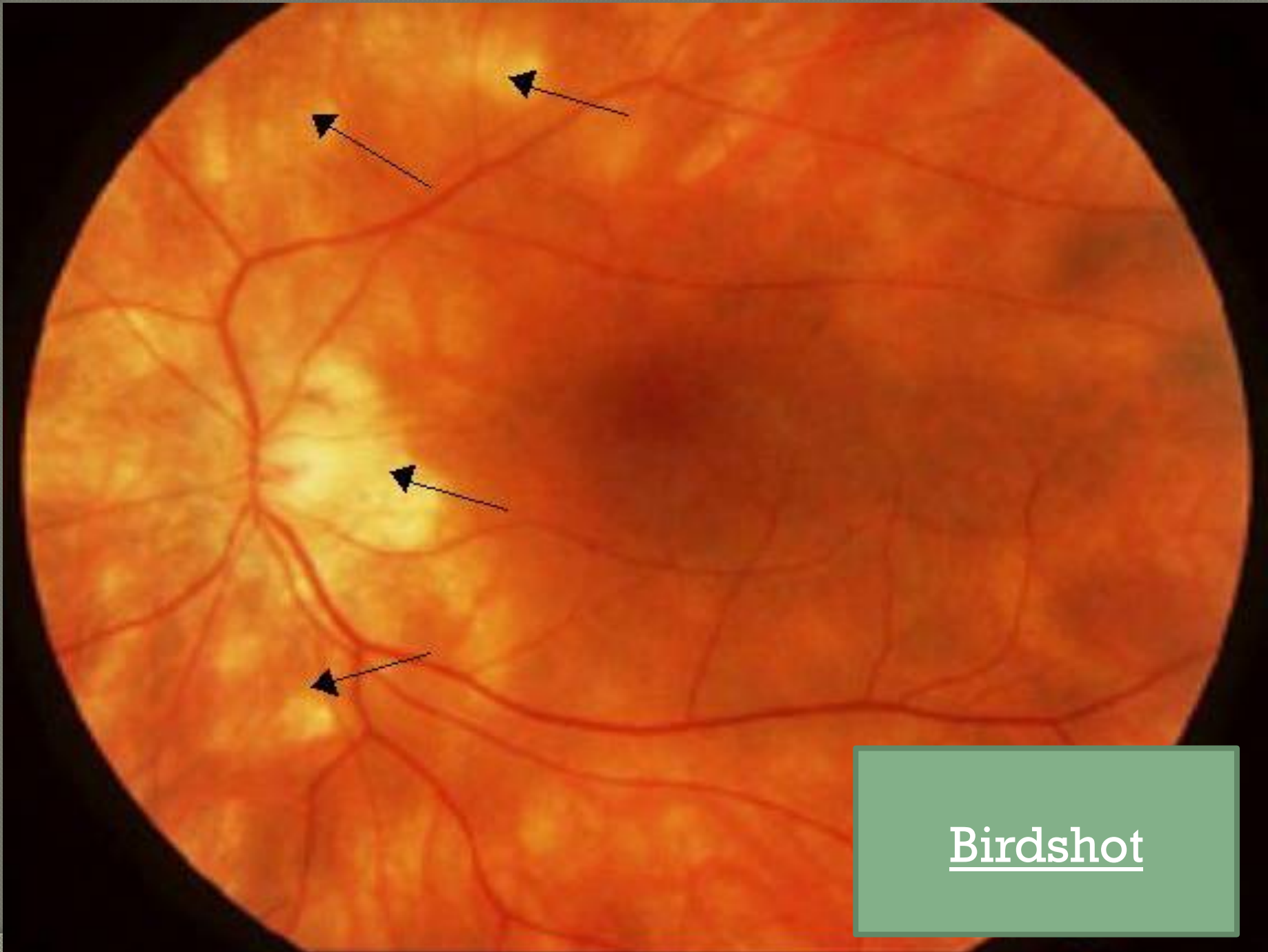
...



CMV

A fundus photograph of the retina, showing a network of blood vessels (arteries and veins) branching across the orange-red surface of the fundus. The vessels are more prominent on the right side of the image.

Virus herpès
zoster



Birdshot

Definition and Epidémiologie : Etiologies

Antérieure

Idiopathique

HLA-B27 associated

Sarcoidose

Herpes

Fuchs

Posner-Scholsman

Lyme

Tbc

Syphillis

Mascarade

...

Intermédiaire

Idiopathique

Sarcoidose

MS

Syphillis

Tbc

...

Post

Toxoplasmosis

Idiopathique

Sarcoidose

Behcet

Herpes

Syphillis

Tbc

Lyme

Toxocara

Birdshot

W D syndrome

Panuvéite

Toxoplasmosis

Idiopathique

Sarcoidose

Behcet

Herpes

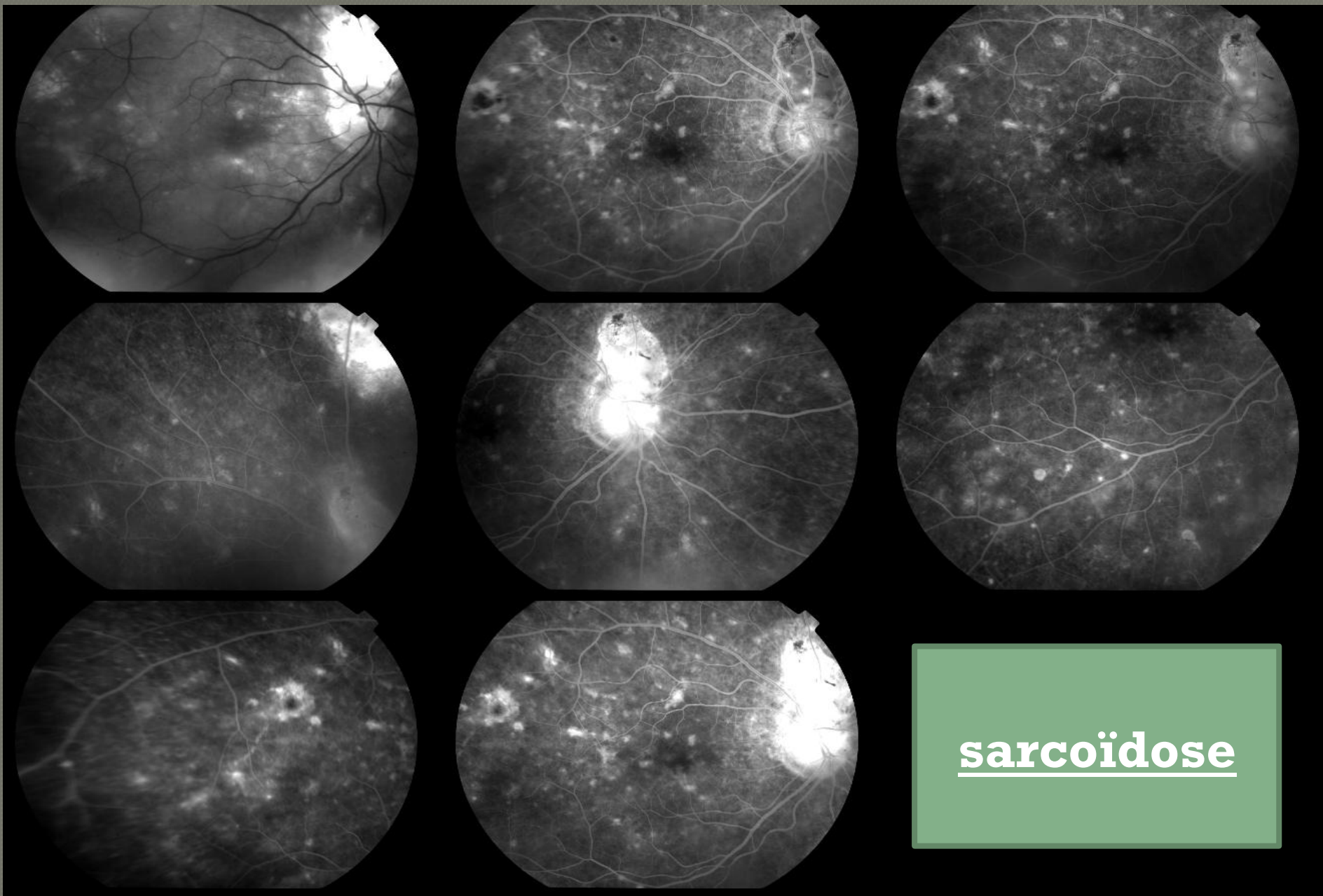
Syphillis

Tbc

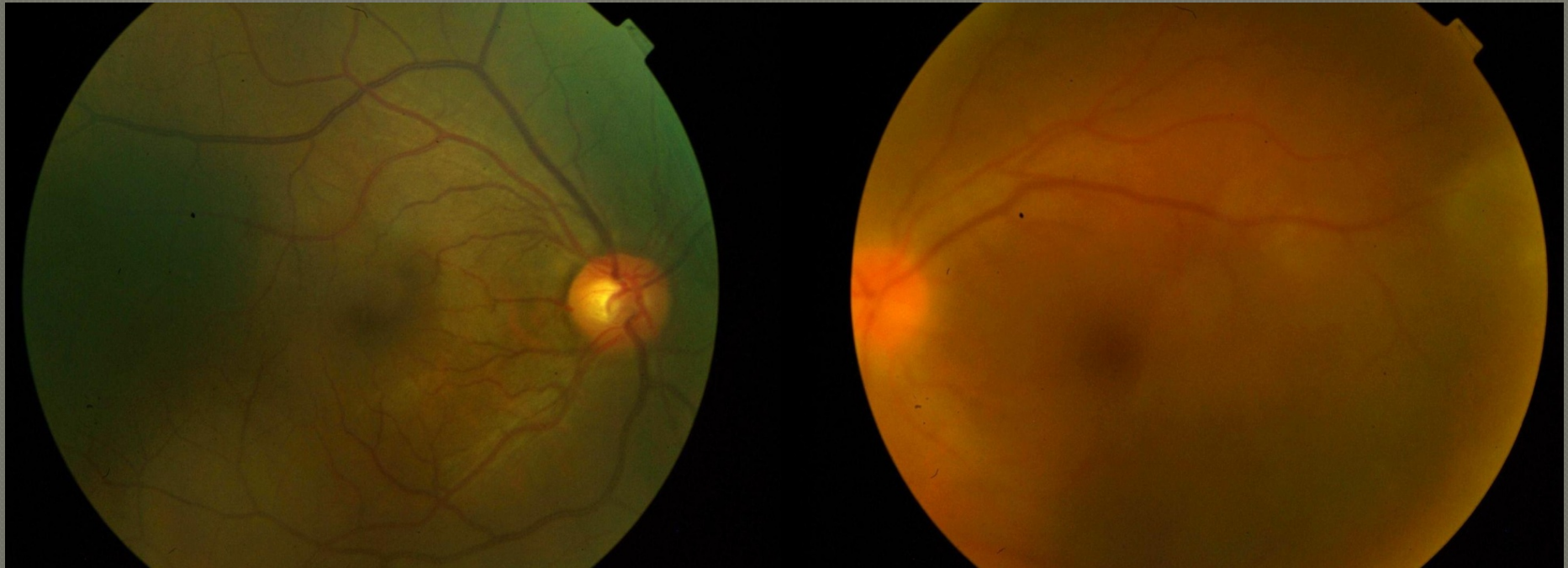
VKH

Opht symp

...



sarcoidose



syphilis

Complications des uvéites

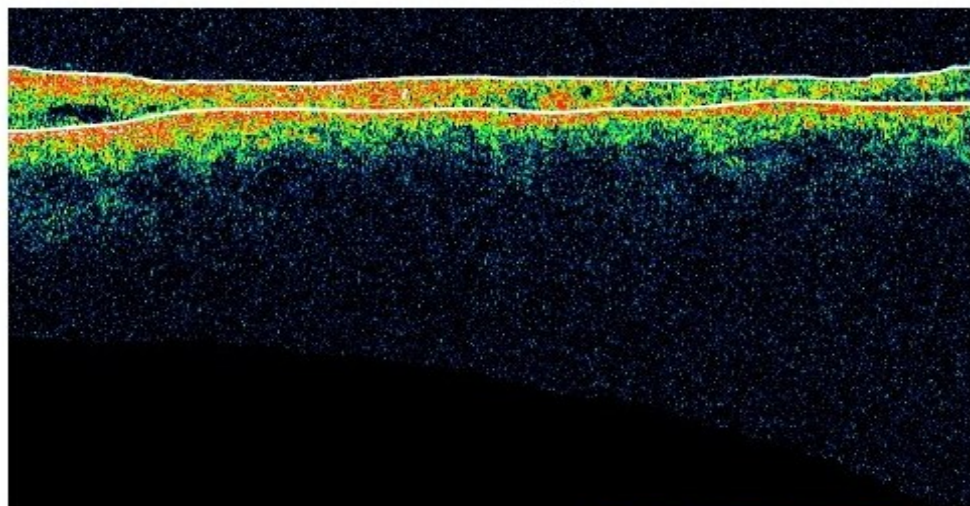
- Œdème maculaire
- Atrophie rétinienne
- Glaucome
- Cataracte
- Kératite en bandelette
- Décollement de rétine



OCT Image

RETINAL MAP ANALYSIS

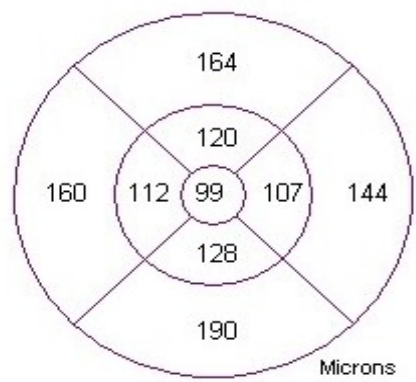
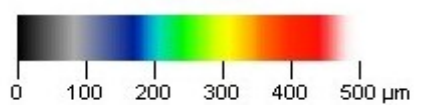
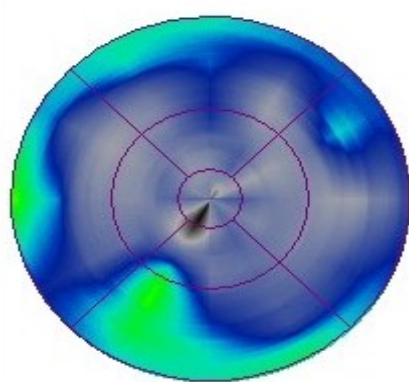

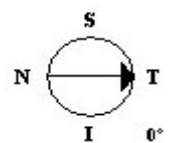
Fundus Image



Signal Strength (Max 10)	6
--------------------------	---

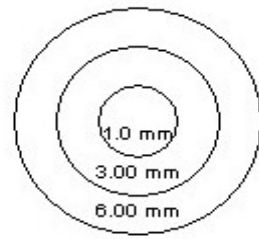


Log Reflection



Microns

- 3.45 mm
- ⊙ 6 mm

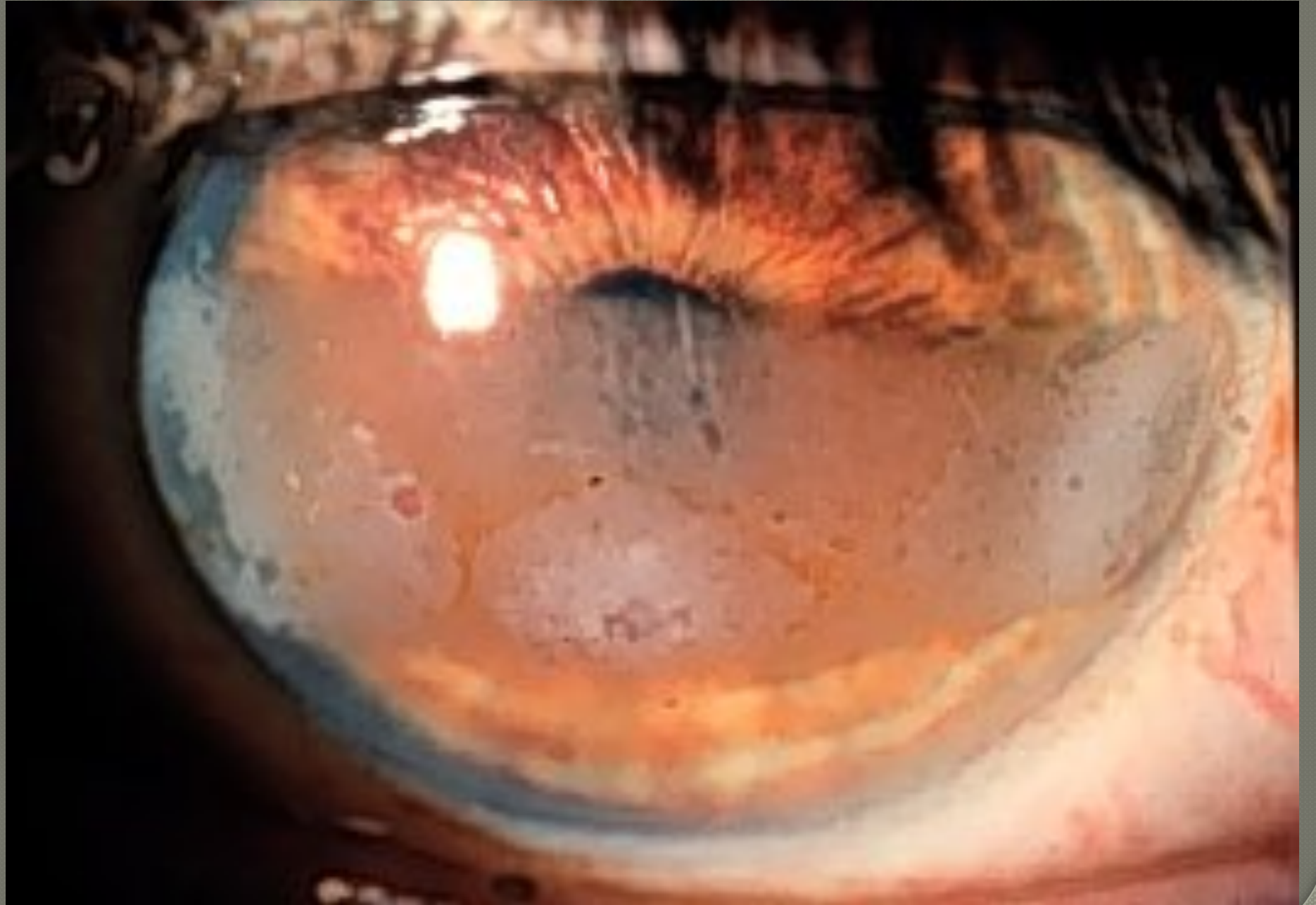

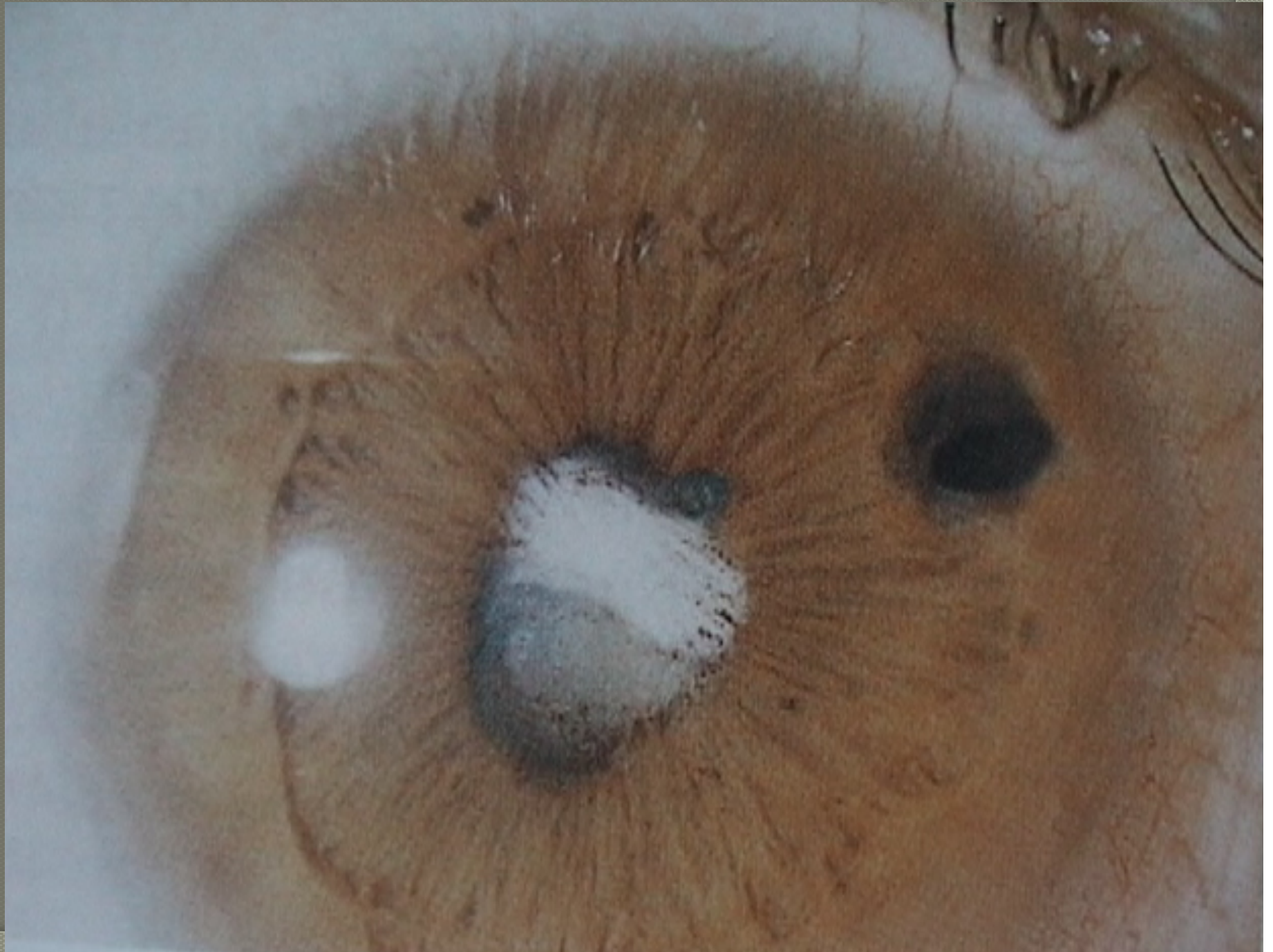Map Diameters

Patient/Scan Information	
Wasim chata x	
DOB: 12/31/1977, ID: NA, Male	
Scan Type	Macular Thickness Map OS
Scan Date	9/27/2005
Scan Length	6.0 mm

Center	95+/-32 microns
Total Volume	4.31 mm ³

Atrophie macula

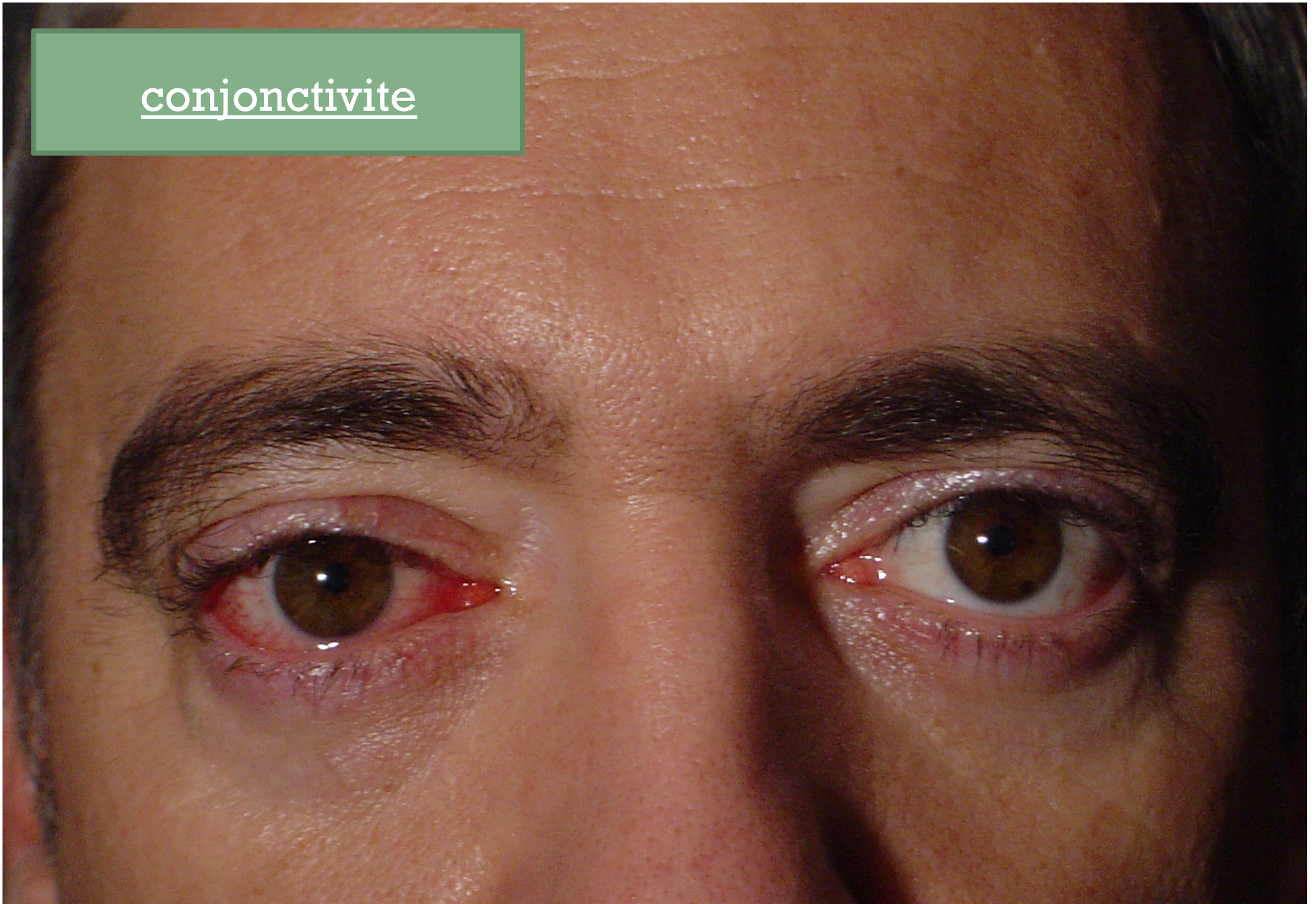

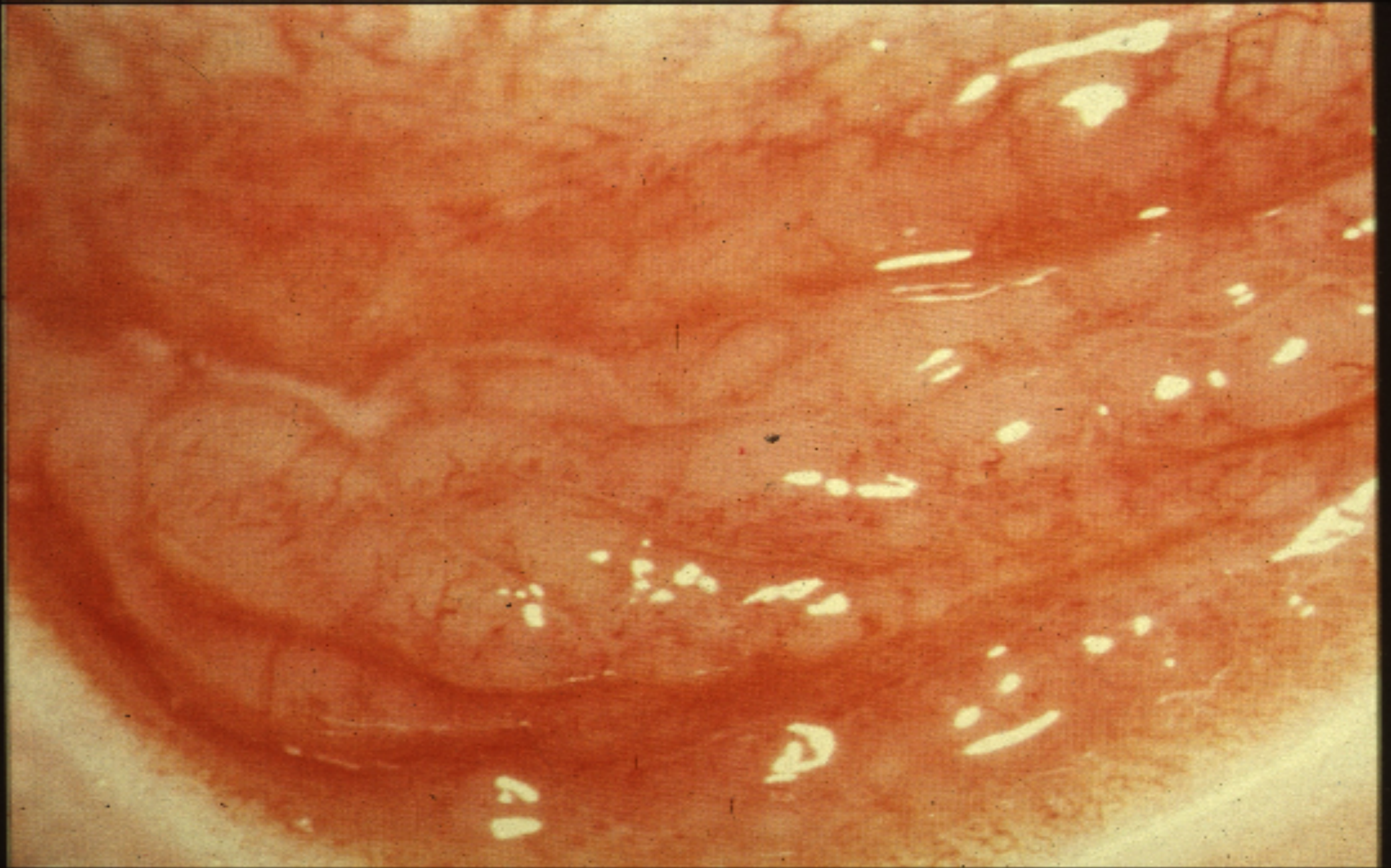


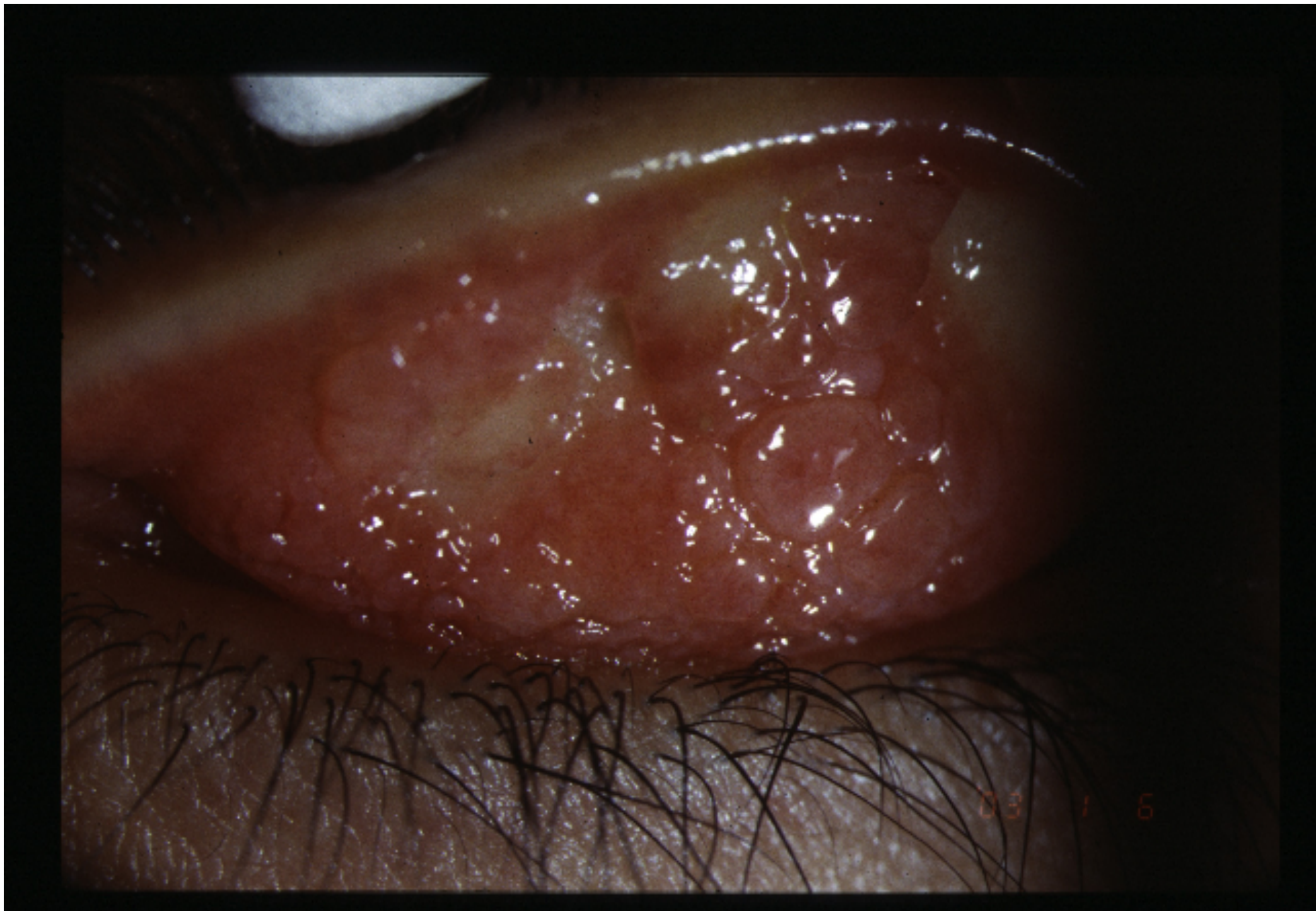
Diagnostic différentiel: Uvéite antérieure aiguë versus œil rouge

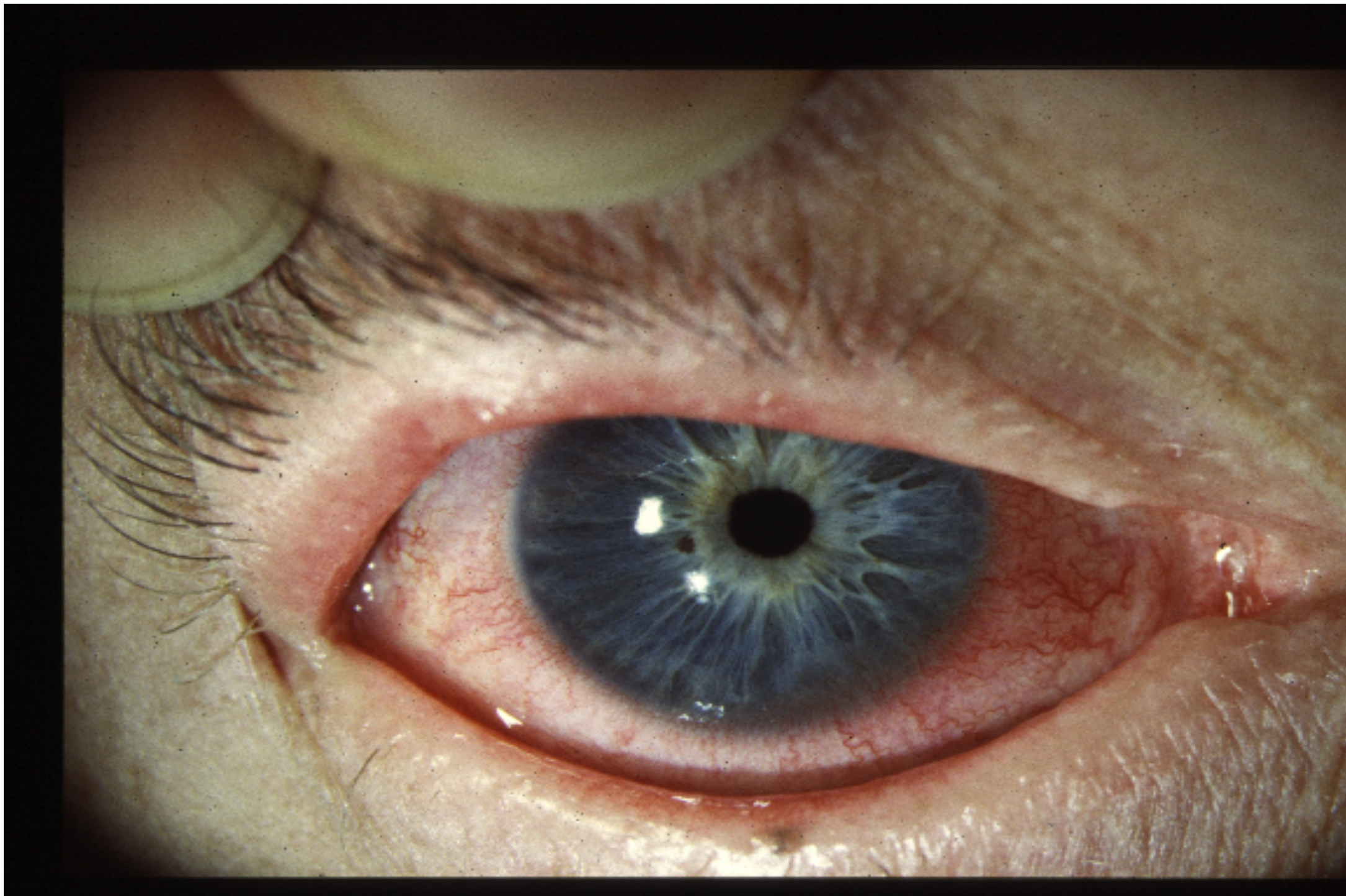
- conjonctivite
- Kérato-conjonctivite sèche
- kératite
- Sclérite
- ophtalmopathie thyroïdienne

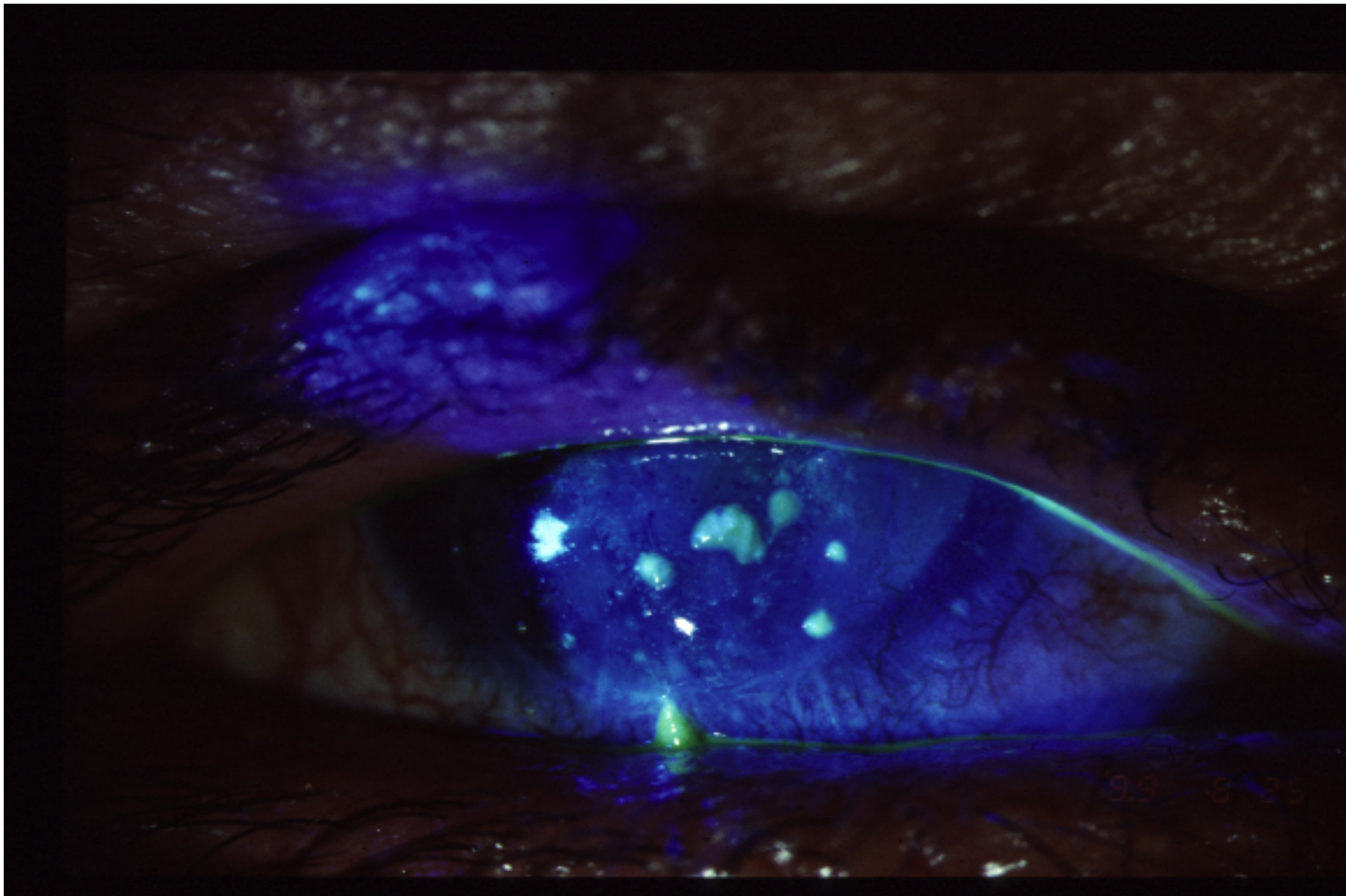
conjonctivite

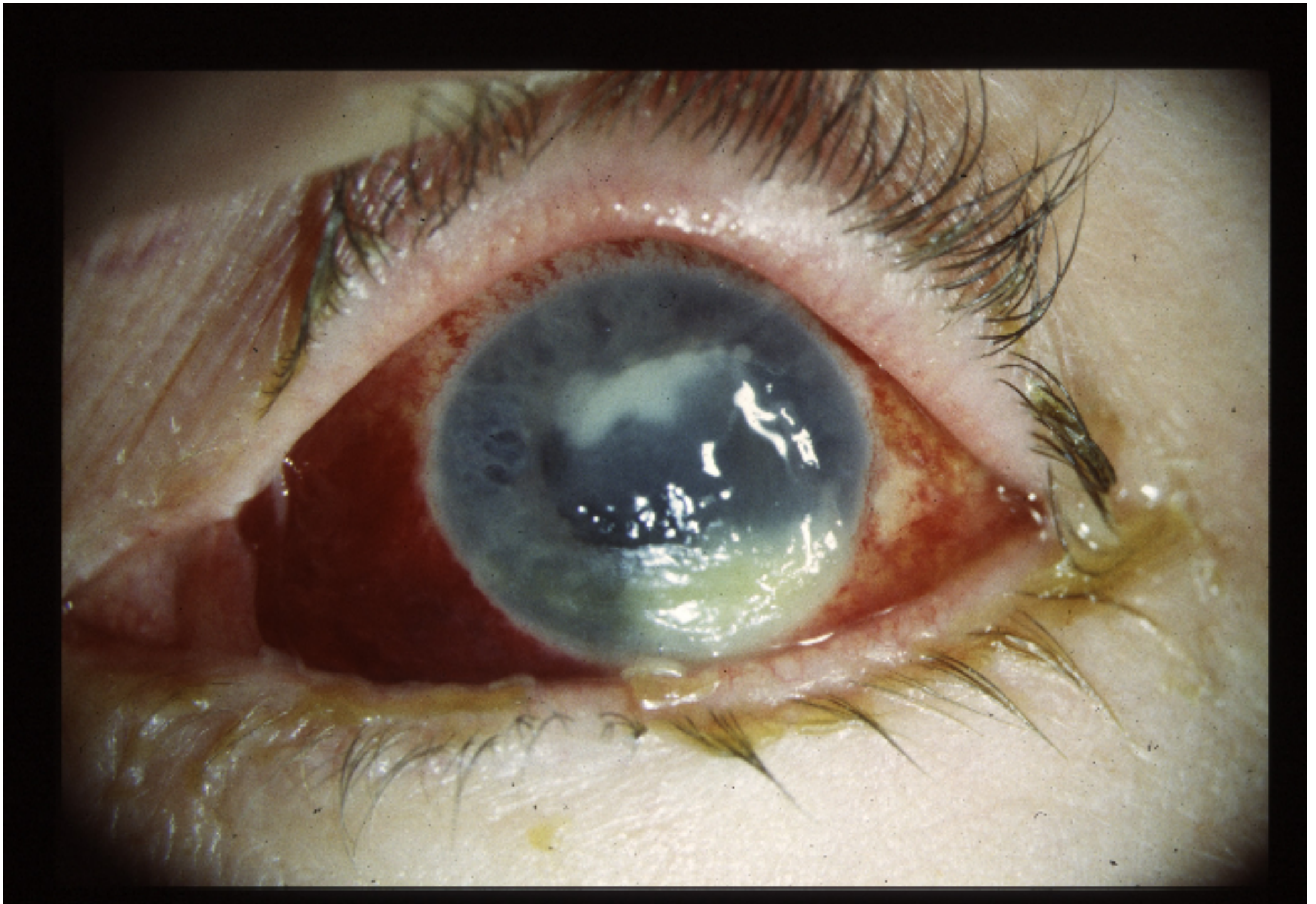


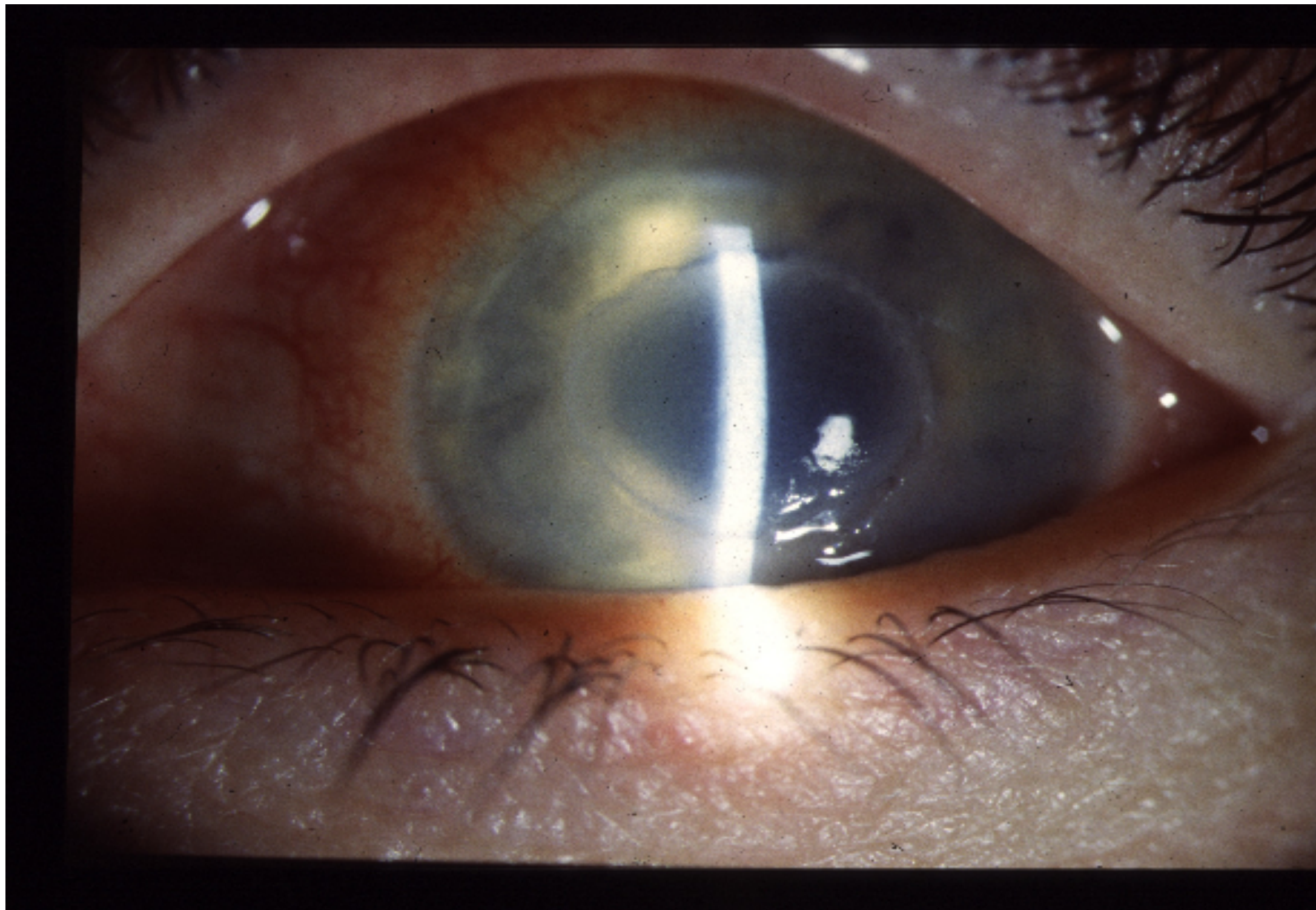


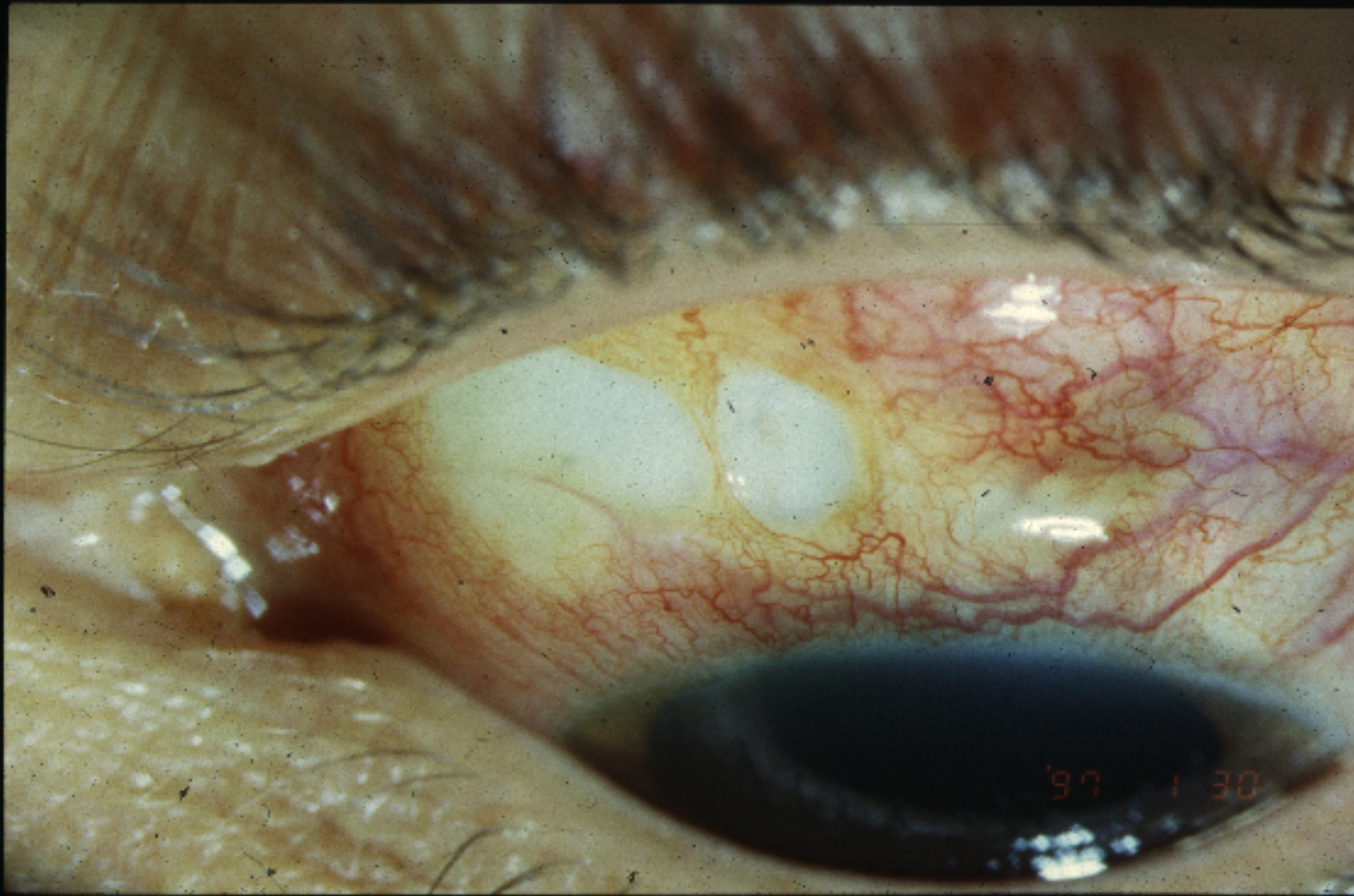

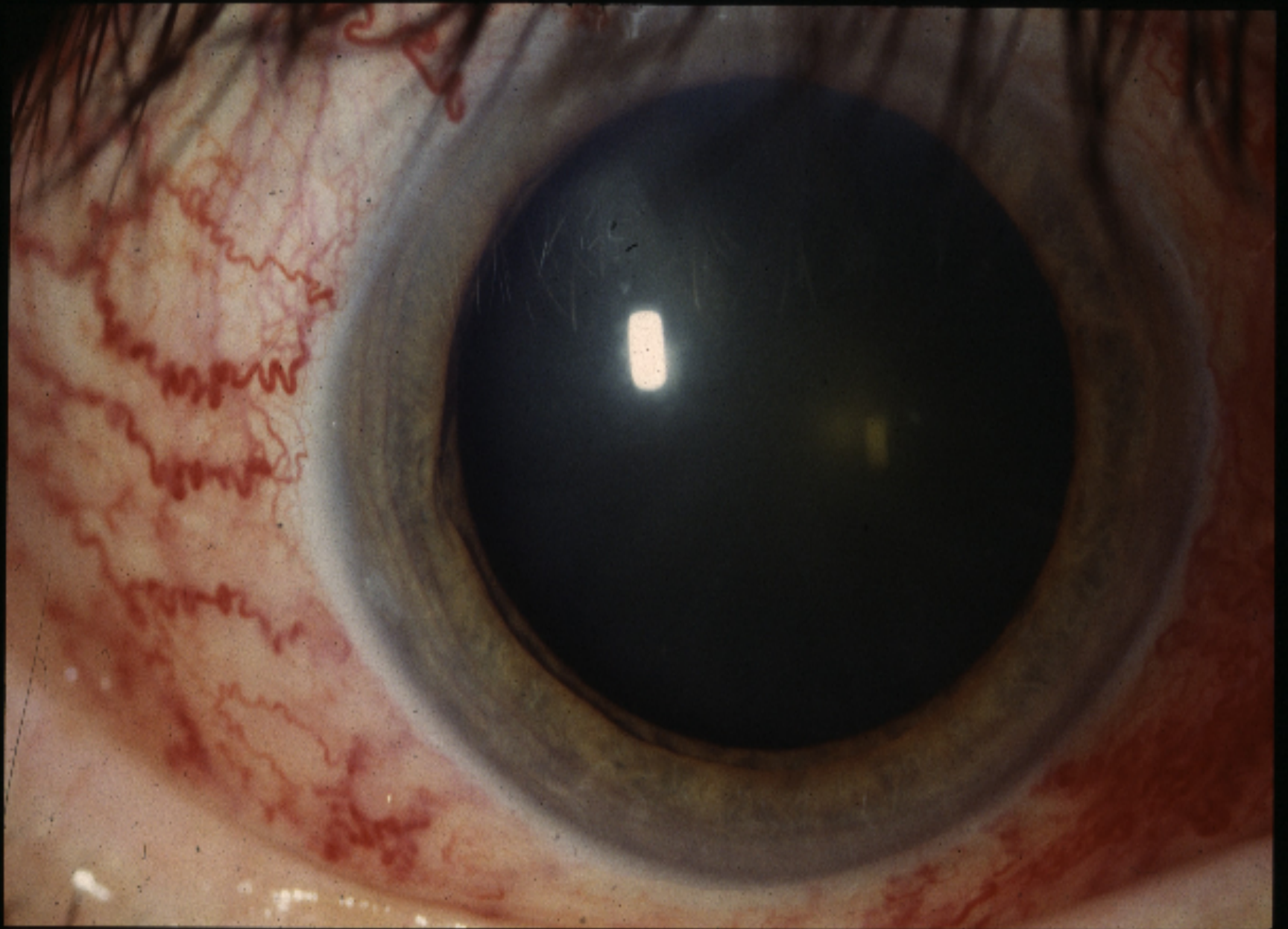












3. SYS*PROS
1T Ex: 16901
1B Set: 2
17 Im: 84+c
.2 T196,0
9 DFOV 15,3cm
STND/I

A 133

HOS. ST PIERRE-ST PIETERS,
KAUR BALJIT
F 32 CT ORB
Apr 11 97
512
Screen Mag = 0,9

L R
7 7
9 3

L
7
9

kV 140
mA 160
Medium
3,0 mm
Tilt : 0,0
1,0 @ 01:15:56 PM



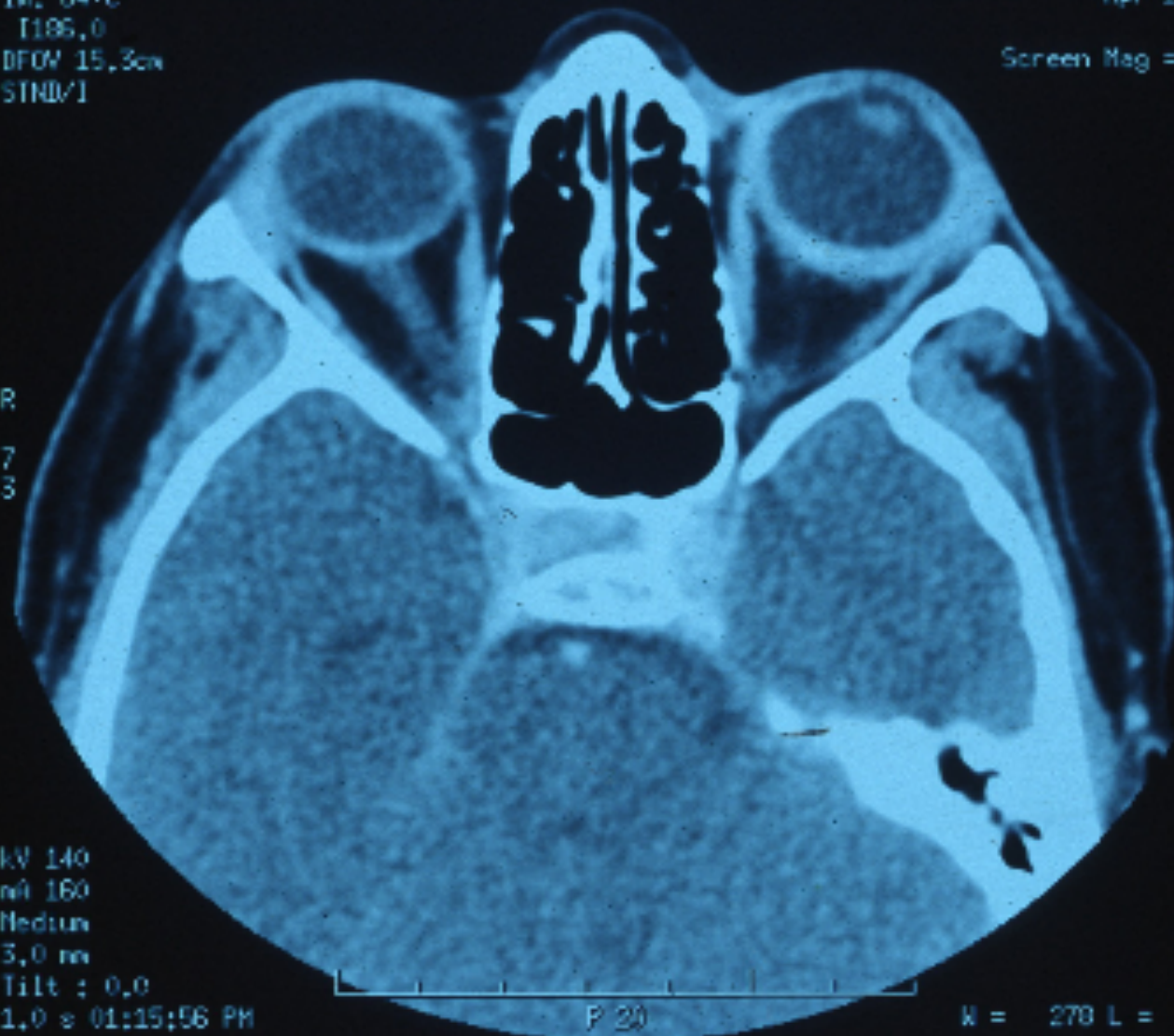
P 20

W = 270 L = 6

SYS*PROS
Ex: 16901

A 133

HOS. ST PIERRE-ST PIETERS,
KAUR BALJIT



Quand suspecter une uvéite lorsqu'un patient se présente en consultation?

Plaintes et signes très divers

- Œil rouge ou blanc
- Œil douloureux ou non douloureux
- Œil rouge ou calme
- Vision normale ou perte de vision
- Iris: couleur ou pupille anormale possible

Pas de lésion visible de la paupière

Pas de lésion visible de la cornée

Pas d'histoire de brûlure, trauma ou CE

Maladie systémique possible

En conclusion:

- Uvéite = inflammation intra-oculaire
- Tous âges (dont jeunes et enfants)
- Sexe: H = F
- Causes infectieuses ou immunes
- Symptômes très variés
- La plus fréquente est l'uvéite antérieure aiguë (D+ en appuyant légèrement sur l'œil + rougeur + photophobie)