

# FEATURES OF AGE-RELATED MACULAR DEGENERATION ON OPTICAL COHERENCE TOMOGRAPHY

VAN KERCKHOVEN W. \*,  
LAFAUT B. \*, FOLLENS I. \*\*, DE LAEY J.J. \*

## ABSTRACT

**Purpose:** To describe Optical Coherence Tomographic (OCT) findings in age-related macular lesions.

**Patients and methods;** We selected 6 patients with characteristic features of age-related macular disease on OCT, 4 of whom presented with Choroidal New Vessels (CNV). OCT is analogous to ultrasound, except that light is used instead of sound. The reflected light is analysed with the technique of low-coherence interferometry.

**Results:** Classic CNV present with well-defined boundaries on OCT, whereas occult CNV can present with well- or poorly defined boundaries. Findings in Chronic Central Serous Chorioretinopathy (CSCR) and Adult Onset Vitelliform Dystrophy (AOVD) need angiographic correlation when compared to findings in CNV.

**Conclusion:** OCT cannot replace conventional diagnostic techniques in exsudative Age-related Macular Degeneration. Although it accurately depicts associated changes and especially the associated serous detachment in macular disease, the imaging of neovascular membranes faces limited penetration and resolution. The interpretation of the tomograms requires further clinico-histological correlation.

## SAMENVATTING

**Doel:** De bevindingen op OCT beschrijven bij leeftijdsgebonden macula-degeneratie.

.....

\* Department of Ophthalmology, Ghent University

\*\* Department of Ophthalmology, Antwerp University

received: 20.04.01

accepted: 13.07.01

**Methode:** Zes patiënten met leeftijdsgebonden maculaire degeneratie en typische letsels op OCT worden besproken. Vier van hen hadden actieve chorioidale neovascularisatie. OCT is analoog aan de echografie, doch gebruikt licht i.p.v. ultratonen. De analyse van het gereflecteerde licht gebeurt door de techniek van 'low-coherence interferometry'.

**Resultaten:** Klassieke membranen tonen welomschreven grenzen op OCT. Occulte membranen kunnen zich ook als slecht-begrensde letsels tonen. Een angiografische correlatie is noodzakelijk bij de diagnosestelling van Chronische Centrale Sereuse Chorioretinopathie en bij de Adult-onset Vitelliforme Dystrofie.

**Conclusies:** OCT toont op adequate wijze de geassocieerde veranderingen bij de exsudatieve maculaire ouderdomsdegeneratie, en meer bepaald de geassocieerde sereuse loslating. De beperkte penetratie en resolutie maken de beschrijving van de neovasculaire membraan zelf moeilijk. Tevens vereist de interpretatie van de tomogrammen verdere clinico-pathologische studie. OCT kan de klassieke diagnostische instrumenten van de exsudatieve leeftijdsgebonden maculaire degeneratie niet vervangen.

## RÉSUMÉ

**Objectif:** Description des images de lésions de DMLA obtenues par OCT.

**Méthodes et patients:** Nous avons sélectionné des images OCT représentatives d'une maculopathie liée à l'âge chez 6 patients, dont 4 présentaient une NVC. L'OCT est analogue à l'ultrasonographie sauf que l'image en OCT est obtenue par réflexion de lumière et non par son. Cette lumière réfléctée est analysée par la technique d'interférométrie de cohérence basse.

**Résultats:** Les membranes classiques sont caractérisées par une nette démarcation. Par contre, les

membranes occultes présentent soit une démarcation nette, soit mal définie. L'interprétation des observations dans la chorioretinopathie séreuse centrale chronique et la dystrophie foveomaculaire vitelliforme de l'adulte nécessite une corrélation avec les données angiographiques.

**Conclusions:** L'OCT ne peut remplacer les techniques diagnostiques conventionnelles. Bien qu'elle évoque les modifications secondaires de façon plus précise, en particulier le décollement séreux associé, la définition par OCT des membranes néovasculaires est limitée. Ces limitations sont dues à une pénétration et une résolution insuffisantes. L'interprétation des tomogrammes nécessite une étude clinico-histologique plus approfondie.

## KEY-WORDS

Optical Coherence Tomography, Age-related Macular Degeneration, Choroidal Neovascularisation, Chronic Central Serous Chorioretinopathy, Adult Vitelliform Foveomacular Dystrophy

## MOTS-CLÉS

Tomographie en Cohérence Optique, Dégénérescence Maculaire Liée à l'Age, Néovascularisation Choroidienne, Chorioretinopathie Séreuse Centrale, Dystrophie Foveomaculaire Vitelliforme

## INTRODUCTION

Choroidal neovascularisation (CNV) is one of the most sight-threatening events that can occur in the macular area.

It is amongst the leading causes of blindness in a patient population over 40 years of age in the Western World(5).

Many patients with exsudative Age-related Macular Degeneration (AMD) do not fulfil the fluorescein angiographic (FA) criteria for treatment required by the Macular Photocoagulation - or Photodynamic Therapy of Subfoveal Choroidal Neovascularisation - Study-guidelines (20,21, 23,24).

Furthermore, the visual prognosis after surgical excision of CNV is depending on the integrity of the adjacent retinal pigment epithelium (RPE) and thus on the relation between CNV and RPE (6,9,16,18,21,26).

Therefore, new imaging techniques are needed to better visualize CNV.

OCT is analogous to ultrasound, except that light is used instead of sound. The analysis of the reflected light is processed with the technique of low-coherence interferometry (1,12,13).

The diagnostic value of OCT in AMD and its role in determining the eligibility for surgery has recently gained attention (8,12,25).

OCT is able to distinguish the cross-sectional morphology of various lesions in both non-exsudative and exsudative AMD: Classic CNV are evident as a thickening and fragmentation of a reflective layer, which corresponds to the RPE and choriocapillaris, and present with well-defined boundaries, but can also include the aspect of a vascularized Pigment Epithelial Detachment (PED). Occult CNV have a variable cross-sectional appearance (12).

We have selected six patients of whom we report the OCT features of CNV in exsudative AMD and Polypoidal Choroidal Vasculopathy (PCV), and compare them to the findings in chronic central serous chorioretinopathy (CSCR) and Adult Onset Vitelliform Dystrophy (AOVD).

## PATIENTS AND METHODS:

OCT findings are reported in six Caucasians with age-related macular lesions, that were diagnosed as: classic CNV (case 1), occult CNV (case 2), recurrent CNV after laser treatment (case 3), PCV with CNV (case 4), chronic CSCR (case 5) and AOVD (case 6).

Fluorangiographic diagnosis was established following the MPS-Guidelines, defining classic vs occult CNV (19).

Indocyanine green angiographic (ICG-A) hyperfluorescence was judged as either a plaque when more than one disc-diameter, a hot spot when smaller than one disc-diameter or as transient choroidal hyperfluorescence (10,11).

OCT determines the time-delay of light reflected from tissue microstructures by interferometry (15). A cross-sectional 2-D image is created from 100 axial scans and mapped to a false color-scale, that indicates the reflectivity of the retinal structures.

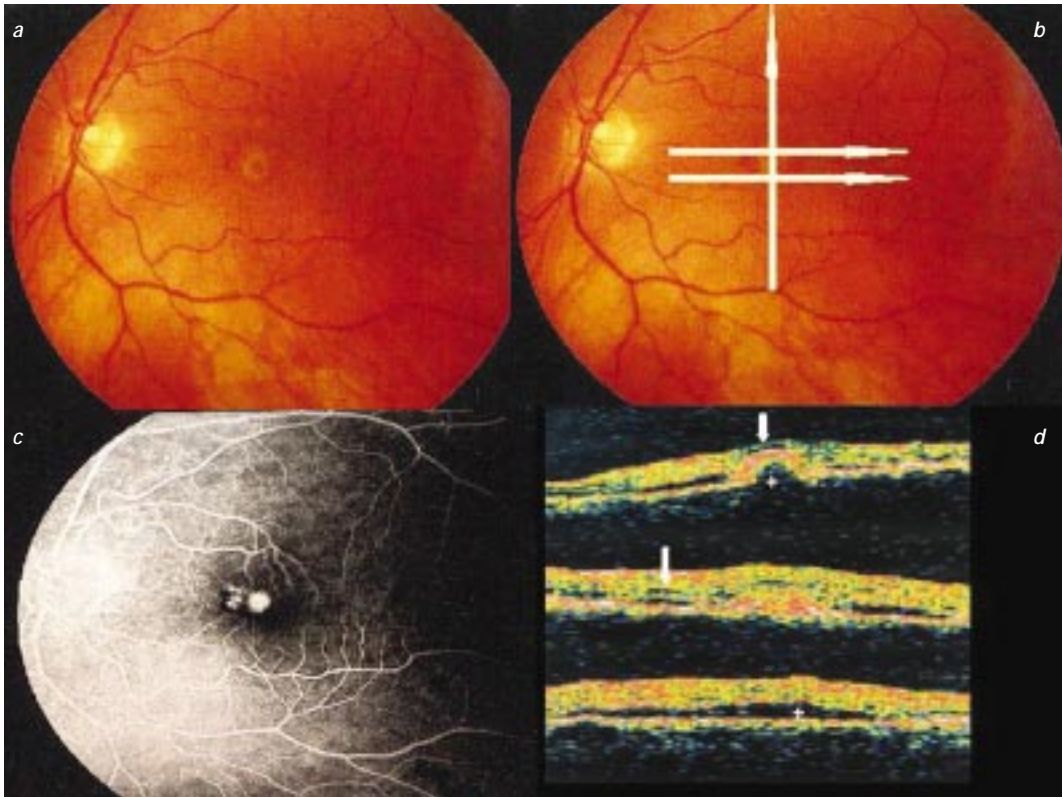


Fig 1: Classic CNV:

1a: Fundus picture

1b: Planes and directions of OCT-scans

1c: Fluorescein angiography, suggestive for classic CNV

1d: OCT shows a well-defined thickening of the RPE-choriocapillaris reflection with dome-shaped configuration centrally (asterisk in superior image) and a purely fusiform thickening at its edges (middle image). Neuroretinal fluid (arrows) and detachment (asterisk in inferior image) are also seen.

OCT was used to examine 6 cases with the aforementioned macular lesions.

The morphological changes as seen on OCT are described and correlated to the FA and ICG-A findings.

The location of each cross-section is indicated by a white line on the corresponding clinical photograph.

## CASE REPORTS:

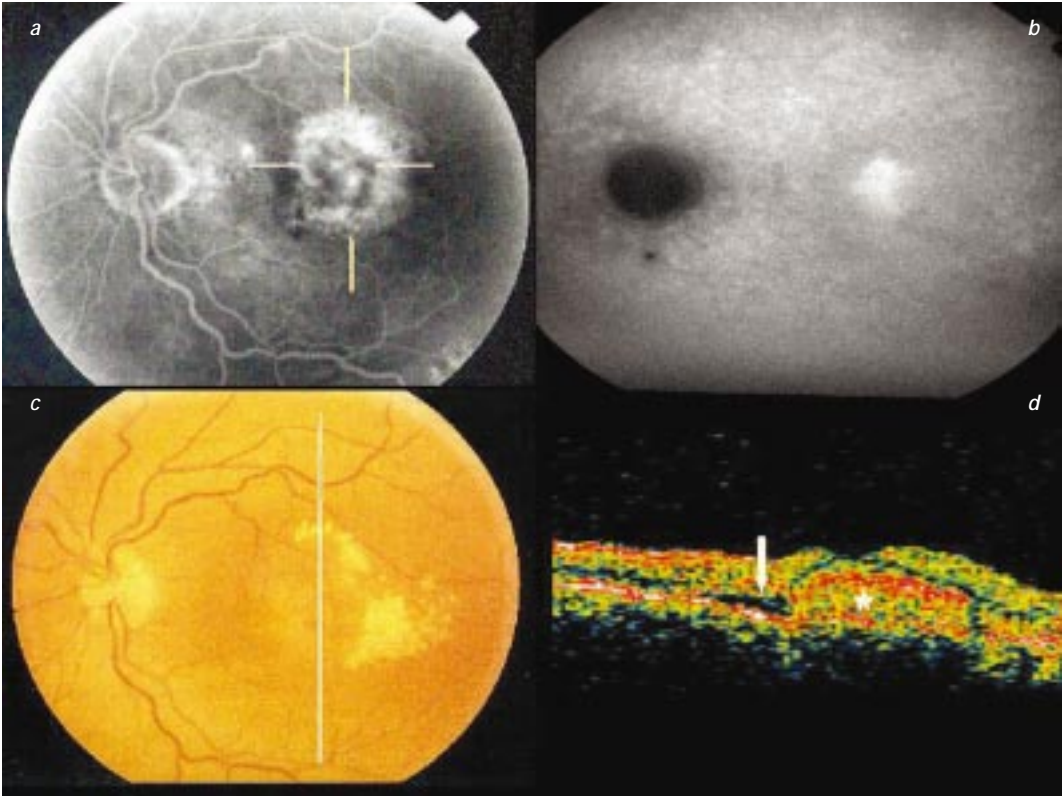
### Case 1: Classic CNV (fig 1)

A 61 year old woman with AMD noted blurred vision in her left eye for 3 months (visual acuity 0.2).

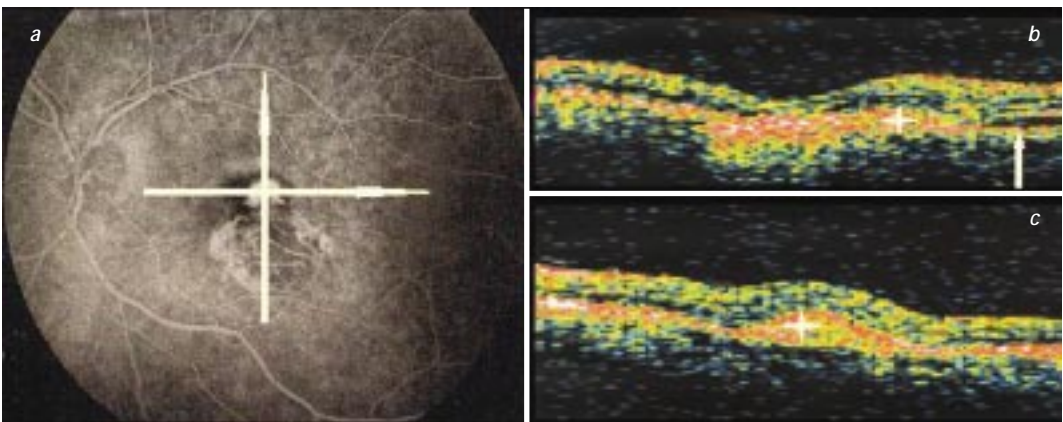
Ophthalmoscopy showed a yellow subfoveal lesion with associated small retinal hemorrhages at its nasal borders.

FA displayed early and progressive hyperfluorescence, consistent with classic CNV. OCT delineated the CNV as a well-defined thickening of the RPE-choriocapillaris reflection, having a dome-shaped configuration centrally. Scanning through its margins revealed a purely fusiform thickening with intermediate high reflectivity. Further visualisation of the CNV beneath the RPE was impossible, the latter almost completely reflecting the incident light.

The CNV was surrounded by a serous neuroretinal detachment, the extent of which could be readily quantified.



*Fig 2:* Occult CNV, Well-defined on OCT in a 76 year old lady: Fluorescein angiography shows late leakage of undetermined source. ICG-A depicts a hot spot corresponding to the central part of the FA-indicated lesion. OCT shows a well-defined thickening of the RPE-choriocapillaris reflection, the extent of which correlates to the extent of the CNV on ICG-A. It also shows a serous neuroretinal detachment.



*Fig 3:* Recurrent CNV 27 months after laser therapy for extra-foveal CNV in a 72 year old man: *Fig 3a:* Subfoveal classic CNV on FA. *Fig 3b:* Vertical scan: Fusiform thickening and elevation of the RPE-choriocapillaris reflection adjacent to the laser-induced scar, the latter showing increased backscatter and thinning of the neuroretina reflection. *Fig 3c:* Horizontal scan through the CNV itself.



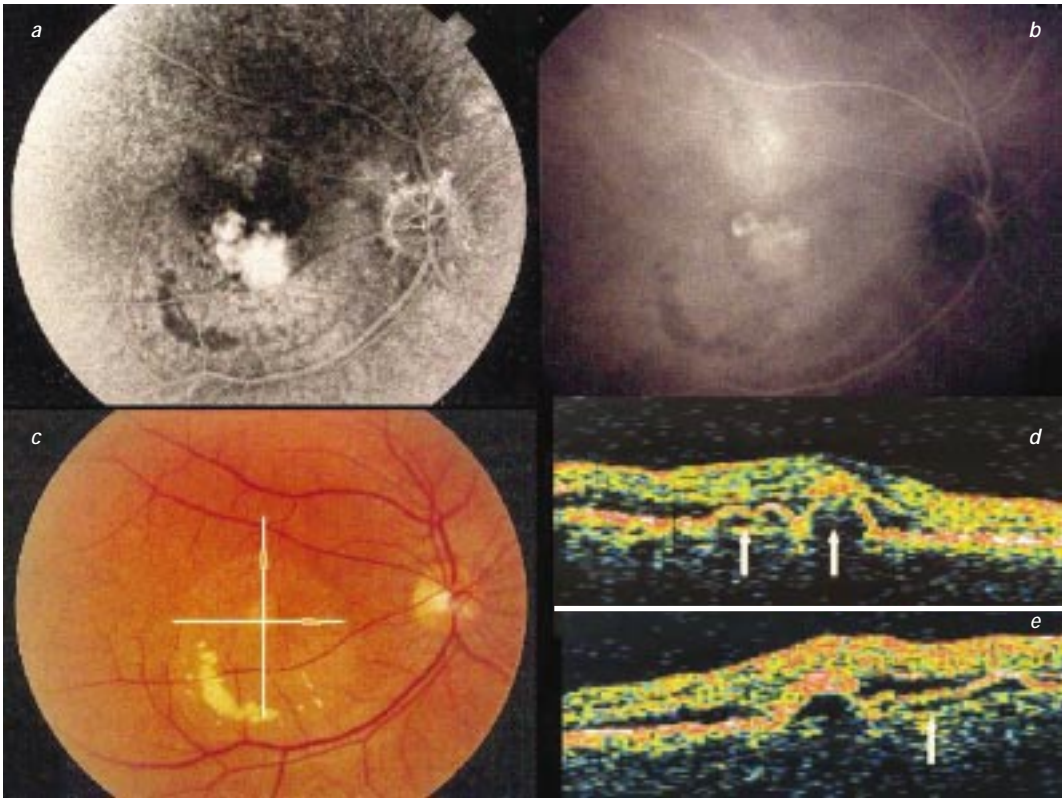


Fig 4: PCV and CNV:

4a: Late leakage from undetermined source on fluorescein angiography.

4b: ICG-A reveals a cluster of polyps adjacent to a plaque.

4c: Scan directions.

4d: Vertical scan shows multiple dome-shaped PED-like lesions with reflective bands beneath them (left arrow), and a fusiform thickening of the RPE-choriocapillaris reflection located at the tip of one such lesion, suggesting CNV (right arrow).

4e: Horizontal scan shows an interconnecting tube-like, optically empty structure (arrow).

Reduced intraretinal optical reflectivity, thickening of the neurosensory retina and loss of foveal contour were consistent with intra-retinal fluid accumulation. The small retinal hemorrhage caused no optical shadowing of the RPE-choriocapillaris reflection.

### Case 2: Occult CNV, Well-defined on OCT (fig 2)

A 76 year old woman with AMD noted decreasing vision in her left eye. Her visual acuity was 0.1. Ophthalmoscopy evidenced a yellowish macular lesion and hard exsudates. Late fluorescein leakage of undetermined source was consistent with occult CNV. ICG-A (fig 2b) depicted a hot spot corresponding to the central

part of the FA-indicated lesion ( horizontal arrows on fig 2a).

OCT showed a well-defined zone of thickening of the RPE-choriocapillaris reflection, the extent of which correlated to the extent of the CNV noted on ICG-A. ( asterisk on fig 2d)

It equally depicted a small serous neuroretinal detachment (SNRD) at its inferior border (arrow on fig 2d).

Only mild thickening of the elevated neuroretina and discrete alteration of the foveal contour were observed.

### Case 3: Recurrent CNV after laser therapy (fig 3)

A 72 year old man was referred for recurrent CNV at the left eye, 27 months after success-

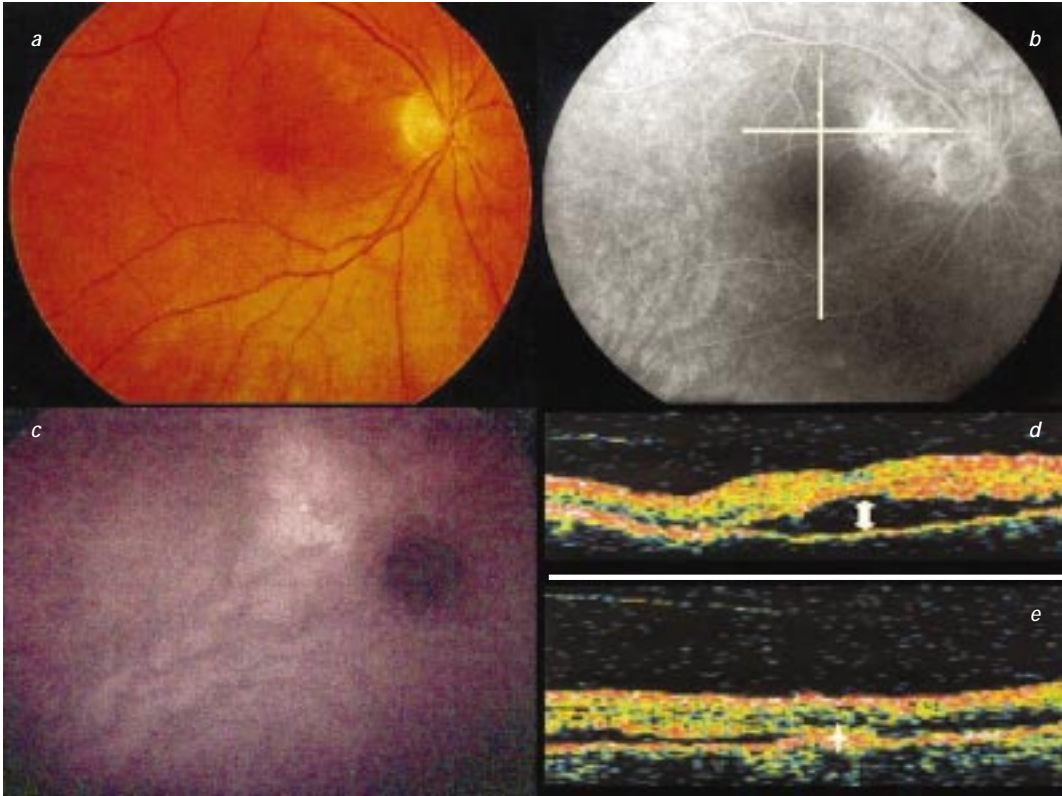


Fig 5: Chronic CSCR in a 60 year old lady:

5a: SNRD of the macula and pigmentary alterations at its superonasal edge.

5b: Pigmentary alterations and discrete leakage on fluorescein angiography.

5c: Transient multizonal hyperfluorescence on ICG-A.

5d: Delineation of the SNRD, which extends to the zone of pigmentary alterations, the latter showing thickening of the RPE-choriocapillaris reflection and increased backscatter from the choroid (asterisk on fig e).

ful laserphotocoagulation of an extrafoveal CNV. Visual acuity had decreased from 0.8 to 0.4. Ophthalmoscopy showed a grey, mildly elevated foveal lesion at the edge of the scar. FA was notable for subfoveal classic CNV (fig 3a). A vertical scan depicted the CNV as a fusiform thickening and elevation of the RPE-choriocapillaris reflection adjacent to the scar (asterisk on fig 3b,c). The latter was characterized by increased backscatter from the choroid due to penetration of light through the atrophic RPE, and by thinning of the neuroretina reflection. There was a small neuroretinal detachment at the superior border of the CNV (arrow on fig 3b). Choroidal vessels seen on FA could not be identified on OCT.

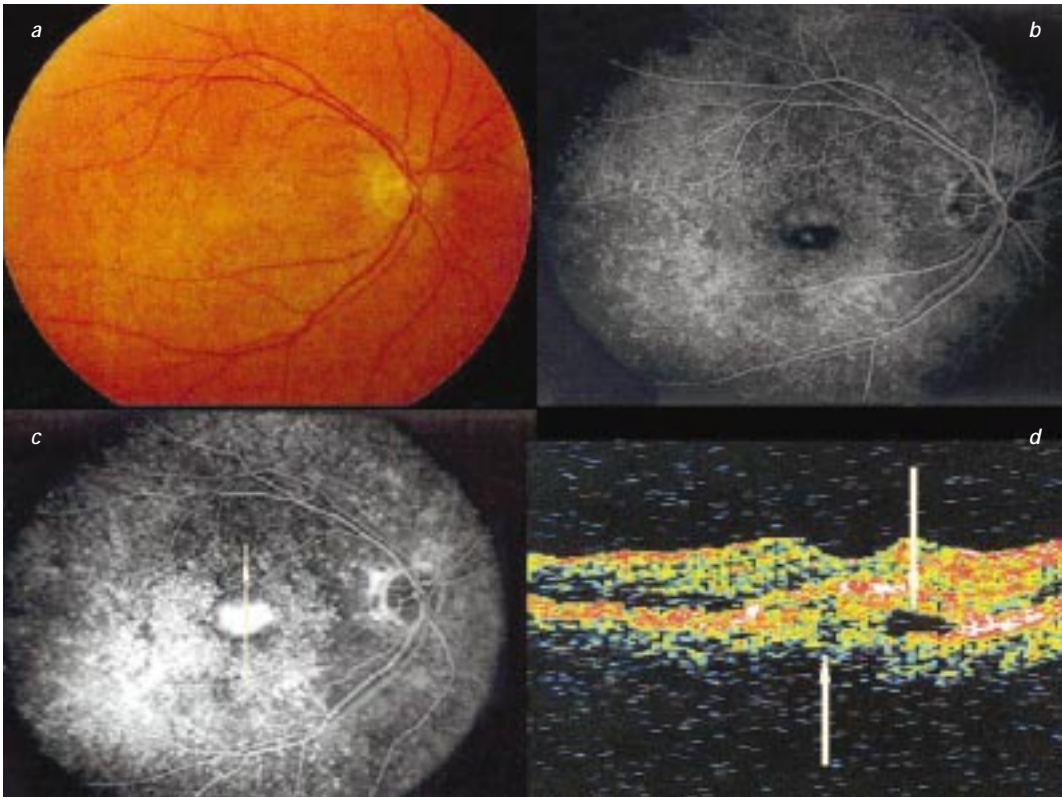
#### Case 4: PCV and CNV (fig 4)

A 55 year old man noted blurred vision at his right eye quite some time before referral. Visual acuity was 0.4.

Ophthalmoscopy showed a yellow subfoveal lesion, longstanding exsudates and SNRD (fig 4c). FA showed well-defined late fluorescein leakage from undetermined source (fig 4a).

ICG-A revealed a cluster of polyps adjacent to a plaque (fig 4b).

Scanning vertically through these lesions showed a cluster of dome-shaped nodular PED-like lesions with relatively high-reflective bands beneath them, and a fusiform thickening of the RPE-choriocapillaris reflection at the tip of one of them, suggesting a CNV. Also we found tube-like structures that seemed to connect two dome-shaped pigmentepithelial detachment-like le-



**Fig 6:** Adult-onset Vitelliform dystrophy in a 62 year old lady:

*6a:* Yellow vitelliform lesion and macular drusen.

*6b and c:* Progressive irregular fluorescence on fluorescein angiography.

*6d:* OCT shows a well-delineated disruption and elevation of the RPE-choriocapillaris reflection with beneath it an inhomogenous reflectivity and optically empty upper part (vertical arrows)

sions. Associated detachment and thickening of the elevated neuroretina were equally seen.

#### **Case 5 : Chronic CSCR (fig 5)**

A 60 year old woman noted blurring and metamorphopsia in her right eye for 6 months, visual acuity measuring 0.3.

Ophthalmoscopy indicated SNRD of the macula and pigmentary alterations at its superonasal edge (fig 5a).

FA confirmed the presence of these pigmentary alterations and showed some leakage.

ICG-A showed transient multizonal choroidal hyperfluorescence but no underlying subretinal new vessels (fig 5c).

OCT delineated the SNRD, that extended to the zone of pigmentary alterations (double-headed arrow on fig 5d). The latter was notable for distortion and thickening of the RPE-chorio-

capillaris reflection, and slightly increased backscatter from the choroid (asterisk on fig 5e).

The detached NS retinal layer showed little thickening and no cystic changes.

#### **Case 6: Adult Onset vitelliform dystrophy (fig 6)**

A 62 year old woman noted slight blurring and metamorphopsia in her right eye for 6 months before examination, visual acuity being 0.8.

Ophthalmoscopy revealed macular drusen and pigment epithelium mottling in both eyes, and a yellow vitelliform central lesion measuring one third disc diameter in the right eye (fig 6a).

This lesion showed irregular hyperfluorescence on FA, first in its superior half and later also inferiorly (fig 6b,c). The yellow material was autofluorescent for infra-red light.



OCT of the central lesion showed a well-delineated fusiform disruption and elevation of the RPE-choriocapillaris reflection with beneath it an inhomogenous reflectivity and an optically empty upper part (vertical arrows on fig 6d). At the edges of this lesion, the red band showed thickening and an irregularly increased reflectivity, suggesting RPE hypertrophy.

## DISCUSSION

Classic CNV is evident as a fusiform thickening of the RPE-choriocapillaris reflection on OCT, with well-defined boundaries. OCT is sensitive for associated structural retinal changes, such as PED, SNRD, retinal edema and attenuation of foveal contour. Thin retinal hemorrhages do not obscure the RPE-choriocapillaris reflection. CNV underneath the RPE however, cannot always be identified because of the reflective characteristics of the RPE, it can include the aspect of a vascularized PED.

Angiographically occult CNV may either present as well- or as poorly-defined on OCT, as has been observed by Hee et al. (12). OCT does not always confirm the extent of CNV as suggested on FA. It appears to correlate better with the findings on ICG-A (case 2).

Chorioretinal atrophy differs from CNV in that it shows pronounced increase in backscatter, no elevation and a thinned and flattened aspect of the overlying neuroretina.

Polypoidal Choroidal Vasculopathy is currently suggested to be a peculiar form of AMD (7, 17). Histological descriptions of PCV locate the fibrovascular tissue inside Bruch's layer, directly underneath the RPE (17).

The OCT findings in polypoidal lesions differ from usual OCT findings of PED in that they present steep elevations of the RPE reflection with a highly reflective band beneath them. The latter has been suggested to represent the choriocapillaris, which could confirm the intra-Bruch location of the polyps (27).

The tube-like connections we found on OCT that seemed to connect the dome-shaped elevations could correspond to the thin walled dilated vessels coursing immediately under the RPE layer, as histologically noted (17).

Fusiform thickening and distortion of the RPE-choriocapillaris reflection was also seen in a pa-

tient with chronic CSCR. It had a more distorted aspect and revealed multifocal increase in backscatter from the choroid, caused by the RPE alterations. Detection and quantification of SNRD is the major advantage of OCT in this disorder. It may reveal angiographically undetected detachments. Hee et al. concluded that OCT was useful as a non-invasive technique for quantitative follow-up of SNRD in chronic CSCR (14).

OCT in a patient with an adult vitelliform lesion can reveal a fusiform alteration of the RPE-choriocapillaris reflection, but with an inhomogenous aspect when compared to the findings in CNV. Thickened and highly reflective aspect of the red layer at its border seems to confirm the hypertrophy of the RPE described histologically and which blocks fluorescence on FA (22). Histological observations of adult vitelliform lesions further include the presence of fusiform eosinophilic collagenous plaques interposed between an atrophic RPE and Bruch's membrane, and the accumulation of lipofuscin within the cytoplasm of RPE cells (22). We found no histologic record of liquefaction and sedimentation of the sub-RPE material but the finding of an optically empty upper part located underneath the RPE-band on OCT could correlate with fluid-level appearance on FA. Increased backscatter from deeper layers is consistent with atrophy of the RPE.

## IN CONCLUSION

OCT provides direct but incomplete structural assessment of CNV in AMD. Classic CNV usually shows as a well-delineated thickening and distortion of the RPE-choriocapillaris reflection, but can also include the aspect of a vascularized PED on OCT. Occult CNV presents with well-or poorly-defined boundaries. Its morphology on OCT however, can be mimicked by other macular disorders, and therefore needs cautious interpretation and angiographic correlation. Many findings require further clinicohistological study. Major problems with the use of OCT in its description of CNV are its limited resolution and its limited penetration through an intact RPE-layer, the scattering and absorptive properties of which influence the reflections from other retinal structures (eg. intra-Bruch fibrovascular tissue). The depiction of the



interrelation between the CNV and the RPE is difficult in most cases (25). Future developments could partially resolve these problems: the use of broad bandwidth Titanium:sapphire laser has shown cross-sectional resolution of biological structures of up to 3 micron (3) and the application of imaging wavelengths further into the infra-red has shown penetration depths of up to 1.5 mm in solid tissue (4).

On the other hand, OCT turned out to be very useful in the assessment of associated changes in AMD, such as edema and detachment of the neuroretina, detachment of the RPE, and subtle changes in foveal contour (2,12,28). OCT provides a non-invasive method for structural monitoring of these associated changes.

**Acknowledgement:** This study was supported by a grant of 'Les Amis des Aveugles'.

#### BIBLIOGRAPHY:

- (1) ALPES J. – Optical Coherence Tomography: image of coherence. *Science*, 1993, 261, 555.
- (2) ANTCLIFF R.J., STARFORD M.R., CHAUHAN D.S., GRAHAM E.M., SPALTON D.J., SCHILLING J.S., FFLYTCHÉ T.J., MARSHALL J. – Comparison between Optical Coherence Tomography and fundus fluoangiography for the detection of cystic macular edema in patients with uveitis. *Ophthalmology*, 2000, 107, 593-599.
- (3) BOUMA B., TEARNEY G.J., BOPPART S.A., HEE M.R., BREZINSKI M.E., FUJIMOTO J.G. – High-resolution Optical Coherence Tomographic imaging using a mode-locked Ti:Al2O3 Laser Source. *Optic letters* 1995, 20, 1486-1488.
- (4) BREZINSKI M.E., TEARNEY G.J., BOUMA B., IZATT J.A., HEE M.R., SWANSON E.A., SOUTHERN J.F., FUJIMOTO J.G. – Optical Coherence Tomography for optical biopsy: properties and demonstration of vascular pathology. *Circulation*, 1996, 93, 1206-1213.
- (5) EVANS JR. – Causes of blindness and partial sight in England and Wales 1990-1991. *Studies on medical and population subjects* 57. London. HSMO, 1995.
- (6) GASS J.D.M. – Biomicroscopic and histopathologic considerations regarding the feasibility of surgical excision of subfoveal neovascular membranes. *Am J Ophthalmol*, 1994, 118, 285-298.
- (7) GASS J.D.M. – Multifocal idiopathic sub-retinal pigment epithelium neovascularisation occurring in darkly pigmented individuals. In: Gass

- J.D.M., ed. *Stereoscopic Atlas of Macular Diseases* 4th ed. St Louis: Mosby, 1997, 1, 250.
- (8) GIOVANNI A., AMATO G.P., MARIOTTI C., SCASSELLATI-SFORZOLLINI B. – Optical Coherence Tomography imaging of Choroidal Neovascularization and its role in the determination of patient's eligibility for surgery. *Br J Ophthalmol*, 1999, 83, 438-442.
- (9) GROSSNIKLAUS H.E., HUTCHINSON A.K., CAPONE A., WOOLFSON J., LAMBERT H.M. – Clinico-pathologic features of surgically excised Choroidal Neovascular membranes. *Ophthalmology*, 1994, 101, 1099-1111.
- (10) GUYER D.R., YANNUZZI L.A., SLAKTER J.S., SORENSEN J.A., HANUTSUKA P., SPAIDE R.F., SCHWARZ S.G., HIRSCHFELD J.M., ORLOCK D.A. – Classification of Choroidal neovascularisation by digital ICG-videoangiography. *Ophthalmology*, 1996, 103, 2054-2060.
- (11) GUYER D.R., YANNUZZI L.A. – Digital Indocyanine Green Angiography of central serous chorioretinopathy. *Arch Ophthalmol*, 1994, 112, 1057-1062.
- (12) HEE M.R., BAUMAL C.R., PULIAFITO C.A., DUKER J.S., REICHEL E., WILKINS JR., COKER J.G., SCHUMAN J.S., SWANSON E.A., FUJIMOTO J.G. – Optical Coherence Tomography of Age-related Macular Degeneration and Choroidal Neovascularisation. *Ophthalmology*, 1996, 103, 1260-1270.
- (13) HEE M.R., IZATT J.A., SWANSON E.A., HUANG D., SCHUMAN J.S., LIN C.P., PULIAFITO C.A., FUJIMOTO J.G. – Optical Coherence Tomography of the human retina. *Arch Ophthalmol*, 1995, 113, 325-332.
- (14) HEE M.R., PULIAFITO C.A., WONG C., DUKER J.S., REICHEL E., RUTLEDGE B., SCHUMAN J.S., SWANSON E.A., FUJIMOTO J.G. – Quantitative assessment of macular edema with Optical Coherence Tomography. *Arch Ophthalmol*, 1995, 113, 1019-1029.
- (15) HUANG D., SWANSON E.A., LIN C.P., SHUMAN J.S., STINSON W.G., CHANG W., HEE M.R., FLOTTE T., GREGORY K., PULIAFITO C.A. – Optical Coherence Tomography. *Science*, 1991, 254 (5035), 1178-1181.
- (16) HUDSON H.L., FRAMBACH D.A., LOPEZ P.F. – Relation of the functional and structural fundus changes after submacular surgery for neovascular Age-related Macular Degeneration. *Br J Ophthalmol*, 1995, 79, 417-423.
- (17) LAFAUT B., AISENBREY S., VANDENBROECKE C., BARTZ-SCHMIDT K.U., HEIMANN K. – Clinico-pathologic correlation in exsudative Age-related Macular Degeneration: Polypoidal Choroidal Vasculopathy. *Retina*. 2000, 20, 650-654.

- (18) LAMBERT HM., CAPONE A., AABERG TM., STERNBERG P., MANDELL BA., LOPEZ PF. – Surgical excision of subfoveal neovascular membranes in Age-related Macular Degeneration. *Am J Ophthalmol*, 1992, 113, 257-262.
- (19) Macular Photocoagulation Study Group. Subfoveal neovascular lesions in Age-related Macular Degeneration: guidelines for evaluation and treatment in the MPS. *Arch Ophthalmol*, 1991, 109, 1242-1257.
- (20) MOISSEIEV J., ALHALEL A., MASURI R., TREISTER G. – The impact of the MPS results on the treatment of exudative Age-related Macular Degeneration. *Arch Ophthalmol*, 1995, 113, 185-189.
- (21) ORMEROD LD., PURKIN JE., FRANK RN. – Long term outcomes after surgical removal of advanced subfoveal neovascular membranes in Age-related Macular Degeneration. *Ophthalmology*, 1994, 101, 1201-1210.
- (22) PATRINELI JR., LEWIS RA., FONT RL. – Foveomacular Vitelliform Dystrophy, Adult-type, A Clinico-pathologic Study including Electron-microscopic observations. *Ophthalmology*, 1985, 92, 1712-1718.
- (23) Photodynamic Therapy of Subfoveal Choroidal Neovascularization in Age-related Macular Degeneration with Verteporfin. TAP Study Group, *Arch Ophthalmol*, 1999, 117, 1329-1345.
- (24) PICCOLINO FC., BOGIA L. – Chronic Central Serous Chorioretinopathy and ICG-A. *Retina* 1994, 14, 231-242.
- (25) SPRAUL CW., LANG GE., LANG GK. – Optical Coherence Tomography of Age-related Macular Degeneration. Correlation of diagnostic techniques of fluorescence angiography and Optical Coherence Tomography. *Klin Monatsbl Augenheilk*, 1998, 212, 141-148.
- (26) THOMAS MA., DICKINSON JD., MELBERG NS., IBANEZ HE., DHALIWAL RS. – Visual results after surgical removal of subfoveal Choroidal Neovascular membranes. *Ophthalmology*, 1994, 101, 1384-1396.
- (27) TAKAHASHI K., OTSUJI T., FUKUSHIMA I., UYAMA M. – Optical Coherence Tomography findings of Idiopathic Polypoidal Choroidal Vasculopathy. *Ophthalmic Surgery and Lasers*, 2000, 31, 210-214.
- (28) WANG M., SONDER B., LUND-ANDERSEN H., LARSEN M. – Detection of shallow detachments in Central Serous Chorioretinopathy. *Acta Ophthalmol Scand*, 1999, 93, 1206-1213.
- .....
- Requests for reprints: Dr Walter Van Kerckhoven,  
Dienst Oogziekten UZ Gent,  
De Pintelaan 185,  
B-9000 Gent, Belgium*

