

BILATERAL CATARACT AND HIGH MYOPIA IN A CHILD WITH TRICHOThIODYSTROPHY: A CASE REPORT

VANDENBERGHE K. *, CASTEELS I. *,
VANDENBUSSCHE E. **, DE ZEGHER F. ***,
DE BOECK K. ***

SUMMARY

Trichothiodystrophy refers to a group of autosomal recessive disorders that have in common brittle sulphur-deficient hair (7). The abnormalities are usually obvious at birth and the clinical expression is variable. Ocular abnormalities are common with bilateral cataract being the most frequent one. We report on a four year old boy with trichothiodystrophy (complementation group TTD-A) who presented to us with strabismus, high myopia and bilateral cataract.

KEY-WORDS:

trichothiodystrophy, bilateral cataract, high myopia

MOTS-CLÉS:

trichothiodystrophie, cataracte bilatérale, myopie

RÉSUMÉ

La trichothiodystrophie fait partie d'un groupe de maladies à transmission autosomale récessive. Elle se caractérise par des cheveux courts et fragiles avec une diminution importante du taux total en soufre (7). Elle regroupe plusieurs affections de sévérité variable. Les anomalies se manifestent généralement dès la naissance. L'anomalie oculaire la plus fréquente est la cataracte bilatérale. Nous présentons un garçon de 4 ans avec trichothiodystrophie (groupe de complémentation TTD-A) avec strabisme, myopie et cataracte bilatérale.

.....

* Dept. of Ophthalmology, University Hospitals St. Rafaël, Capucijnenvoer 33, 3000 Leuven, Belgium

** Dept. of Paediatrics, St-Elisabeth Hospitals, Nederrij 144, 2200 Herentals, Belgium

*** Dept. of Paediatrics, University Hospitals Gasthuisberg, Herestraat 49, 3000 Leuven, Belgium

received: 22.05.01

accepted: 26.07.01

INTRODUCTION

Trichothiodystrophy (TTD), or sulfur-deficient brittle hair, is a rare autosomal recessive neuroectodermal disorder. Clinical features of TTD vary widely ranging from the isolated hair defect to a severe spectrum of neuroectodermal symptoms. TTD has previously been referred to as BIDS (brittle hair, impaired intelligence, decreased fertility and short stature), IBIDS (also including ichthyosis), PIBIDS (including photosensitivity) or Tay syndrome, depending on the range of manifestations in this heterogeneous disorder (2). Examination on UV damaged fibroblasts revealed a DNA repair defect and more specifically, a defect in the extremely rare TTD-A complementation group. In most cases, the repair defect involves the same gene as in xeroderma pigmentosum group D or less commonly type B. Ocular problems as bilateral cataract, strabismus and retinal dystrophy have been reported in patients with trichothiodystrophy (1,4,5). We describe a four year old boy with TTD and impaired vision due to cataract and associated high myopia.

CASE REPORT

A four year old boy was referred to the ophthalmological department because of poor vision. He was born at 36 weeks of gestation to healthy and non consanguineous parents after an uneventful pregnancy. Birth weight was 2,3 kg (<P3) and length 48 cm (P3-P25). Clinical examination showed a 'collodion baby' with ichthyosis, brittle hair and nails and an indurated leather-like occiput. The ears were dysplastic but had a normal implantation. He suffered a neonatal infection due to *Staphylococcus Aureus* and *Candida Parapsilosis*. During the first year he developed respiratory problems with bronchial hyperreactivity and asthma, treated by inhalation of steroids. An IgE mediated allergy was diagnosed but an underlying immune deficiency, as has been described in this syndrome was not present. Psychomotor delay became evident over years and there was severe growth retardation (height and weight <3th percentile). Growth retardation has been described in TTD, but in our patient was also secondary to the glucocorticoid intake for skin and pulmonary problems.

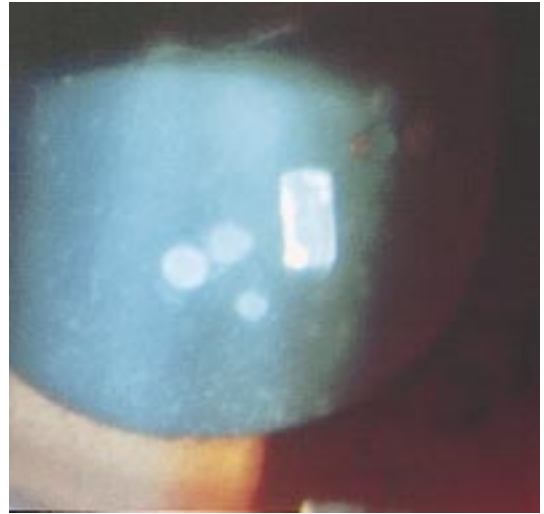


Fig 1. Biomicroscopic examination revealed punctate opacities in all layers of the lens.

Ophthalmological examination at the age of 3.5 years showed an alternating convergent strabismus with normal eye motility. There was no nystagmus. Binocular visual acuity (Ffooks test) was 6/60 for distance and 6/24 for near. Biomicroscopic examination of the anterior segment showed bilateral punctate lens opacities in all layers of the lens (Figure 1). Fundoscopy showed a myopic appearance of the posterior pole and cycloplegic streak retinoscopy revealed a myopia of -12 diopters at the right eye and -14 diopters at the left eye and astigmatism of +1.75 cyl/110° at the right and +2.75 cyl/40° at the left eye. Two months later the binocular vision for distance had improved to 3/9. The binocular near vision was 6/18. Biomicroscopic examination revealed no change in the lenticular opacities.

DISCUSSION

Trichothiodystrophy refers to a group of autosomal recessive disorders that have in common short brittle hair that is low in the high-sulfur amino acid components and high in the low-sulfur components compared to normal (2). The term was first coined by Price et al. (7) in 1979 to describe a neuroectodermal complex. The hair defect is the common feature in all patients. Impaired intelligence, decreased fertility, short stature, ichthyosis, photosensitivity,

Table 1 Variants of trichothiodystrophy (by Petrin et al. ref *Pediatr Dermatol* 1998;15:31-4)

Type	Affected	Eponym/Acronym
A	Hair +/- nails.	
B	Hair + nails + mental retardation.	Sabinas
C	Hair +/- nails + mental retardation + folliculitis + retarded bone age +/- caries.	Politt
D	Brittle hair + infertility + developmental delay + short stature.	BIDS
E	Ichthyosis + BIDS. Hair +/- nails + mental retardation + short stature +/- decreased gonadal function +/- lenticular opacities/cataracts +/- failure to thrive/"progeria" + microcephaly +/- ataxia +/- calcifications of the basal ganglia + erythroderma and scale.	Tay Syndrome IBIDS
F	Photosensitivity + IBIDS.	PIBIDS
G	Trichothiodystrophy with immune defects. Hair +/- mental retardation + chronic neutropenia or immunoglobulin deficiency.	
H	Trichothiodystrophy with severe IUGR. Hair + severe IUGR + FTT + developmental delay + recurrent infections + cataracts + hepatic angioendotheliomas.	

IUGR = intrauterine growth retardation.

FTT = failure to thrive.

dysmorphia, nail and teeth dysplasia, increased susceptibility to infections due to chronic neutropenia or immunoglobulin deficiency and axial osteosclerosis are present in some patients as well (1,3). In addition to mental retardation, neurological involvement may include spasticity with pyramidal signs; hyperreflexia; spinocerebellar signs such as nystagmus, dysarthria, tremor and ataxia; peripheral neuropathy with the absence of deep tendon reflexes and neurosensory hearing impairment (1). Pulmonary bronchiectasis and hepatic angioendotheliomas have also been found in association with trichothiodystrophy (4).

The syndromes of trichothiodystrophy have been grouped based upon the associated abnormalities. Several different classification systems have been developed. These are useful to the extent that they allow grouping of individuals for prognosis. Table 1 summarizes the recognised categories of trichothiodystrophy in ascending order of severity (6).

Our patient had the typical features of brittle hair, ichthyosis, dysplastic ears, growth- and psychomotor retardation. Respiratory problems were present.

The most frequently reported ophthalmological finding is bilateral cataract tending to be small and punctate (4). Other reported abnormalities are retinal dystrophy (1), astigmatism, strabismus, retrobulbar haemangioma (5) and spinocerebellar signs e.g. nystagmus (4). Our patient showed the characteristic punctate cataract in combination with a mild degree of nucleosclerotic changes, alternating convergent

strabismus and high myopia. There was no nystagmus. On funduscopy myopic changes of the posterior pole, but no characteristics of a retinal dystrophy were visualised. A flash ERG was not performed because of the anaesthetic risk. Pathologically, the fibroblasts of many patients with TTD, with or without clinical photosensitivity, have a defect in the DNA excision repair after ultraviolet damage. In most cases, the genetic basis for the repair defect is located in the same gene as in xeroderma pigmentosum group-D (XPD-ERCC2) or less commonly type B (XPB-ERCC3). Another third group (TTD-A) has recently been discovered. The three genes now identified encode proteins that form a subunit of the transcription factor TFIIH (general transcription factor IIH) complex that regulates gene transcription and may direct repair enzymes to sites of damage. They are critical for the function of the nucleotide repair system, which repairs damaged DNA by using the complementary strand as a template. The transcription defects can be broad-reaching and are likely to be responsible for other clinical findings in TTD. The pathology of TTD appears to lie in a DNA repair defect (explaining the photosensitivity) as well as in a transcription defect (2,3). Interestingly, in TTD, the defective repair of ultra-violet damaged DNA is not associated with skin cancer, unlike other DNA repair diseases. Cockayne's syndrome is another rare inherited neuroectodermal disorder in which patients have a defect in UV-sensitive nucleotide excision repair without increased skin incidence of cancer (2). Patients with Cockayne's syndrome are

sensitive to sunlight, have short stature and have the appearance of premature ageing. In the present patient, the DNA repair synthesis in fibroblasts after UV damage was defective and further complementation examination revealed a defect in the TTD-A group. Sun protection of the skin has been advised to the patient.

Biochemically, the diagnosis of trichothiodystrophy is based upon the presence of characteristic hair findings: "zig-zag" pattern of light and dark bands on polarizing microscopy and a low cystine content measured by ion exchange chromatography (6).

The absence of an effective treatment for TTD points to the need for antenatal diagnosis in cases where there is a positive family history (8). Two sets of circumstances arise:

- The family is "informative": some patients with TTD exhibit defective repair of ultraviolet-light irradiated DNA. In families with this deficiency, antenatal diagnosis can be accomplished by testing cells from amniotic fluid drawn at 16 or 18 weeks of gestation. DNA repair defects can be revealed even earlier in trophoblast cells removed by biopsy during the 10th week of pregnancy.
- No DNA repair defect can be demonstrated: hair abnormalities, which are always present in TTD, can be revealed in the fetus at approximately 20 weeks of gestation by electronmicroscopy of fetal hair or by biochemical studies of the sulfur-containing amino acid content of the hair (3).

In conclusion we described the ophthalmological findings in a four year old boy with trichothiodystrophy, bilateral cataract and high myopia. Cycloplegic refraction and correction of the refractive error in children with this syndrome is important as visual improvement can

be obtained after spectacles have been prescribed.

REFERENCES

- (1) BATTISTELLA P.A., PESERICO A. – Central nervous system dysmyelination in PIBI(D)S syndrome: a further case. *Child's Nerv Syst* 1996; 12: 110-113
- (2) CHEN E., CLEAVER J.E. – Trichothiodystrophy: clinical spectrum, central nervous system imaging, and biochemical characterization of two siblings. *J Invest Dermatol* 1994; 103 (5 Suppl): 154S-158S
- (3) FOULC P., JUMBOU O. – Trichothiodystrophy: evolutive aspects. *Ann Dermatol Venereol* 1999; 126:1-5
- (4) HAPPLE R., TRAUPE H. – The Tay syndrome (congenital ichthyosis with trichothiodystrophy). *Eur J Pediatr* 1984; 141: 147-52
- (5) MEYNADIER J., GUILLOT B. – Trichothiodystrophie. *Ann Dermatol Venereol* 1987; 114: 1529-36
- (6) PETRIN J.H., MECKLER K.A. – A new variant of trichothiodystrophy with recurrent infections, failure to thrive and death. *Pediatr Dermatol* 1998; 15:31-4
- (7) PRICE V.H., ODOM R.B. – Trichothiodystrophy. Sulfur-deficient brittle hair as a marker for neuroectodermal symptom complex. *Arch Dermatol* 1980; 116:1375-1384
- (8) SARASIN A., BLANCHET-BARDON C. – Prenatal diagnosis in a subset of trichothiodystrophy patient defective repair. *Br J Dermatol* 1992; 127:485-91

.....

*Request for reprints:
Vandenberghé Kathy,
Oogheekunde
U.Z. Sint-Rafaël
Kapucijnenvoer 33,
B-3000 Leuven*