

# LONG-TERM FOLLOW-UP OF CENTRAL SEROUS CHORIORETINOPATHY (CSCR)

KANYANGE M.L.\* & DE LAEY J.J.\*

## SUMMARY

We studied retrospectively the clinical files of 6 patients (11 eyes), who were diagnosed as CSCR between 1968 and 1986. They were all males, aged from 28 to 46. The initial diagnosis of CSCR was based on the clinical symptoms and ophthalmic findings. It was supported by fluorescein angiography and later also by ICG angiography.

Eight eyes have been treated by laser. After a follow-up of at least 15 years:

- 2 of the treated eyes and one untreated eye developed subretinal neovascularization;
- 6 of the treated eyes and one untreated eye progressed to diffuse pigment epitheliopathy;

Final visual acuity was less than 2/10 in 6 eyes.

## RÉSUMÉ

Nous avons effectué une étude rétrospective concernant 6 patients (11 yeux) dont le diagnostic de chorioretinopathie séreuse avait été posé entre 1968 et 1986. Ils étaient tous mâles, âgés de 28 à 46 ans. La période de suivi était de 15 ans au moins.

Le diagnostic initial a été posé sur base de la symptomatologie clinique et de l'examen du fond d'oeil. Il a été confirmé par l'angiographie fluorescéinique et plus tard également par l'angiographie au vert d'indocyanine. Huit yeux ont été traités au laser.

Après un suivi d'au moins 15 ans:

- 2 yeux traités au laser et un oeil non-traité ont développé une néovascularisation sous-rétinienne;
- 6 yeux traités au laser et un oeil non-traité ont évolué vers une épithéliopathie pigmentaire diffuse;

L'acuité visuelle finale était inférieure à 2/10 dans 6 yeux.

## SAMENVATTING

We deden een retrospectieve studie van de klinische dossiers van 6 patiënten (11 ogen), waarbij de diagnose van centrale sereuze chorioretinopathie gesteld werd tussen 1968 en 1986. Alle patiënten waren mannen waarvan de leeftijd schommelde tussen 28 en 46 jaar.

De diagnose werd gesteld op grond van de klinische symptomen en van het fundusonderzoek.

Ze werd bevestigd door de fluoresceïne-angiografie en later door de indocyaninegroen-angiografie. Acht ogen werden behandeld met laser.

Na een follow-up van minstens 15 jaar:

- evolueerden 2 met laser behandelde ogen en één onbehandeld oog naar subretinale neovascularisatie;
- evolueerden 6 met laser behandelde ogen en één onbehandeld oog naar diffuse pigmentepitheliopathie;

De uiteindelijke gezichtsscherpte bedroeg minder dan 2/10 in 6 ogen.

## KEY-WORDS

central serous chorioretinopathy (CSCR) - subretinal neovascularization - diffuse retinal pigment epitheliopathy

## MOTS-CLÉS

choriorétinite séreuse centrale - néovascularisation sous-rétinienne - épithéliopathie rétinienne diffuse

.....

\* *Department of Ophthalmology, University of Ghent, Belgium*

received: 11.03.02

accepted: 23.04.02

## INTRODUCTION

Central serous chorioretinopathy (CSCR), first reported by von Graefe (12) in 1866, is defined as an idiopathic serous detachment of the macula due to the accumulation of serous fluid under the neurosensory retina (5, 13, 14). It causes a mild transient loss of central vision in otherwise healthy young to middle-aged individuals often with a type A personality (14). Male patients are predominant in the reported series. The main complaints are: metamorphopsia, a positive scotoma and micropsia. Permanent visual loss can occur because of chronic or recurrent disease.

Long-term follow-up suggests possible evolution to age-related macular degeneration

In this study, we present the clinical and angiographic findings in 6 patients, who were diagnosed with CSCR and who were on average seen 15 years later with complaints of progressive visual loss.

## METHODS

We studied retrospectively the clinical files of 6 patients (11 eyes) who were diagnosed as CSCR between 1968 and 1986.

They were all males, aged from 28 to 46 (average age: 37) and the follow - up period was

at least 15 years. Their medical and family history were unremarkable. All 6 patients denied chronic corticosteroid use.

The diagnosis of CSCR was suspected on the basis of symptoms like decreased central vision, a central scotoma, metamorphopsia or micropsia, serous retinal and RPE detachments and typical ophthalmoscopic features such as retinal pigment epithelium changes and subretinal precipitates.

The diagnosis was supported by fluorescein angiography.

Eight eyes underwent laser treatment.

## RESULTS

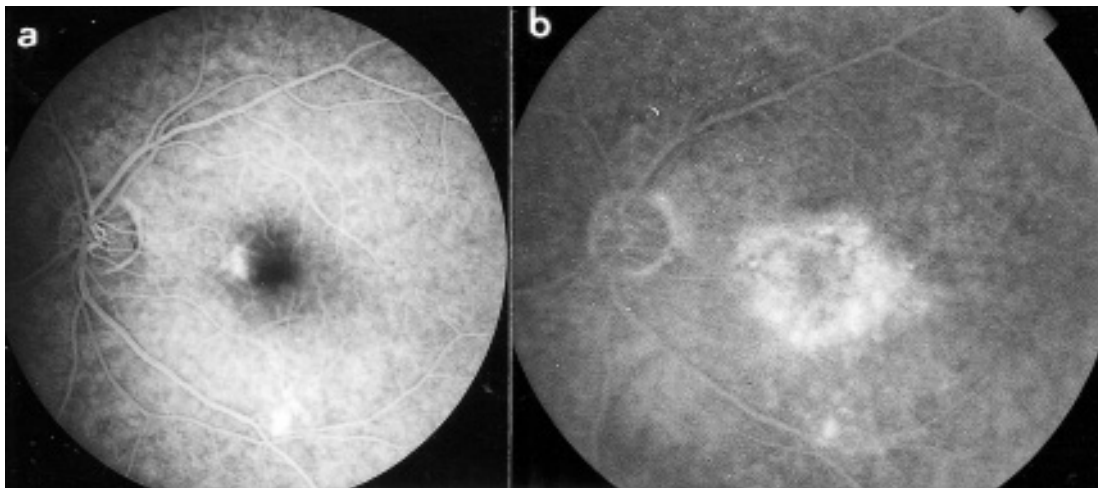
After a follow-up of at least 15 years by patients with CSCR, 7 eyes progressed to a diffuse pigment epitheliopathy, one eye still showed persistent subretinal fluid at last examination. Three eyes eventually developed subretinal neovascularization.

The final visual acuity was less than 2/10 in 6 eyes.

We summarize 4 illustrative cases:

### CASE 1:

A 43-year-old man complained in 1982 of recent visual loss in his left eye. His visual acuity was 12/10 in the right eye and 10/10 in the



*Fig 1.* Case 1: Left eye:  
a. fluorescein angiography in August 1982  
b. fluorescein angiography in February 2000

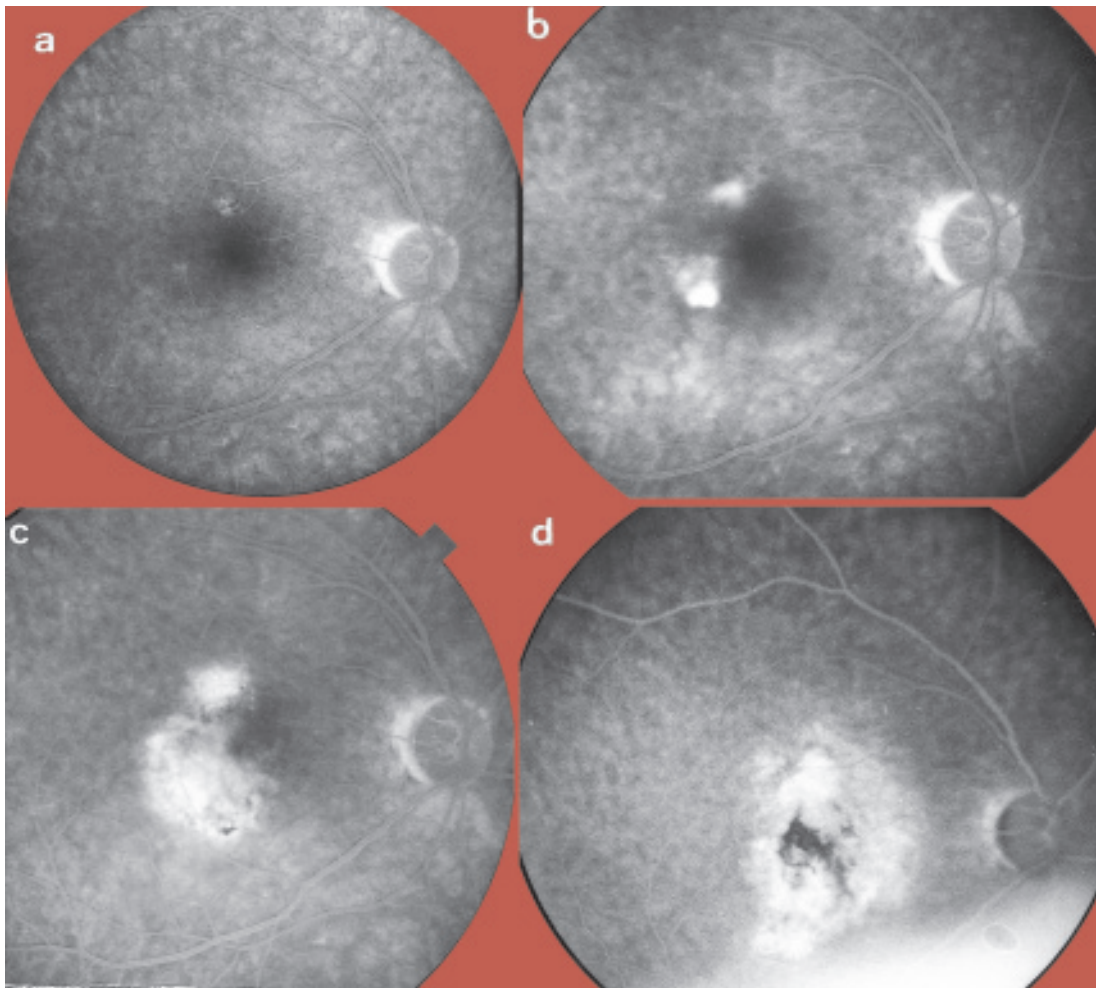


Fig 2. Case 1: Right eye:

- a. fluorescein angiography in August 1982  
Note the two areas of RPE changes
- b. fluorescein angiography in March 1995  
Serous detachment and leakage

- c. fluorescein angiography in August 1995  
Presence of subretinal neovascularization
- d. fluorescein angiography in February 2000  
Atrophic scars.

left. Fluorescein angiography revealed the presence of two diffusion points, one nasal to the fovea and one above the inferior temporal arcade (fig. 1a). He had been treated with argon laser in his left eye (fig. 2a).

Three years later, in December 1985, he came back complaining of decreased vision with metamorphopsia in the left eye. The best corrected visual acuity was 15/10 in the right eye and 8/10 in the left eye.

An ophthalmoscopic examination revealed some pigment epithelial changes in the macular re-

gion in both eyes. In the left eye fluorescein angiography revealed a diffusion point and a serous detachment. The left eye was not treated. In March 1995, the patient came back complaining of decreased vision in the right eye. His visual acuity was 2/10 in his right eye and 10/10 in his left eye. On funduscopy, the right eye showed a serous detachment of the neurosensory retina with diffusion spots temporally to the macula on fluorescein angiography (fig. 1b). He underwent laser treatment in his right eye.

Four months later, in July 1995, further decrease of visual acuity was noticed in the right eye and juxtafoveal subretinal neovascularization was detected. Laser therapy was performed in his right eye (fig. 1c).

At the last follow-up visit, in February 2000, the best corrected visual acuity was counting fingers in his right eye and 8/10 in his left eye. Fluorescein angiography showed an atrophic macular scar in the right eye (fig. 1d) and pigment epithelial changes without leakage in his left eye (fig. 2b).

#### CASE 2:

A 34-year-old man complained in 1979 of blurred vision in his left eye.

Best corrected visual acuity was 15/10 in the right eye and 8/10 in the left eye. Ophthalmoscopic examination revealed a serous retinal detachment with subretinal precipitates in his left macula.

Follow-up visits showed a stable visual acuity without diffusion on fluorescein angiography.

Two years later, in April 1981, the patient complained of further decrease of vision in his left eye, although visual acuity was 15/10 in his right eye and 8/10 in his left eye.

Ophthalmoscopic examination revealed a serous detachment in his left eye.

Fluorescein angiography showed a leakage point situated inferonasally of the serous detachment. The right eye was considered normal. He underwent laser treatment in his left eye.

Three years after the laser treatment of May 1981, he complained again of decreased vision in the left eye. Visual acuity was 20/10 right and 15/10 left. Ophthalmoscopic examination revealed some atrophic scar nasally under the fovea and parafoveal pigment epithelial changes. There was no serous detachment and no leakage on fluorescein angiography.

He was seen again in 1996 and 2001 and showed a stable visual acuity. The fundoscopic findings remain unchanged.

At his last visit the final visual acuity was 12/10 in the right eye and 8/10 in the left eye.

#### CASE 3:

A 44-year-old man complained of decreased vision in the left eye. He presented a corneal scar

in his left eye due to an injury by a metallic foreign body. Visual acuity was 15/10 in his right eye and 8/10 in his left eye. A serous pigment detachment was seen on fundoscopy, no leakage zone was observed on fluorescein angiography in his left eye.

Six years later, in July 1991, he complained of decreased visual acuity in the right eye. Visual acuity was 5/10 in the right eye and 8/10 in the left eye. Fluorescein angiography showed a diffusion point nasally to the fovea in his right eye and pigment epithelial changes in the left eye. The patient was not treated.

Seven years later, in March 1998, the patient complained of further decrease of visual acuity in his right eye. Visual acuity was 2/10. Fluorescein angiography showed an atrophic area centrally and a leakage point temporally to the macula. Indocyaninegreen angiography revealed multiple zones of transient hyperfluorescence.

The patient underwent laser treatment. Five months later the visual acuity was 1,5/10 and an atrophic scar was noted on fundoscopy.

At the last visit in February 2001, the patient complained of decreased vision in his left eye. The visual acuity was 1,5/10 in the right eye and 4/10 in the left eye.

Ophthalmoscopic examination showed some irregular atrophy of the pigment epithelium in the right eye and some subfoveal fibrine depots in the left eye without apparent leakage on fluorescein angiography.

#### CASE 4:

A 35-year-old man complained of decreased visual acuity and accommodation problems in both eyes. Visual acuity was 12/10 in both eyes. In the right eye ophthalmoscopy and fluorescein angiography showed some pigment epithelial alterations and a serous detachment temporarily under the macula and diffusion in the late phase. In the left eye some pigmentary changes in the macula with 3 diffusion points were seen. Both eyes underwent laser treatment.

Three years later, in October 1982, the patient came back complaining of decreased vision in the left eye. A recurrence was noted, with a smoke stack diffusion nasally to the fovea on

fluorescein angiography. The patient underwent laser treatment.

In february 1994, a recurrence was noted in the right eye. Visual acuity was 2/10 in the right eye and 10/10 in the left eye. Fluorescein angiography revealed a parafoveal neovascular membrane which was treated with laser.

A fluorescein control performed 5 months later showed no more diffusion.

In June 2001, he complained of decreased vision in the left eye. The visual acuity was 1,5/10 in the right and 5/10 in the left eye. Fluorescein angiography showed some pigment epithelial alteration in his right eye and a persistent serous detachment without diffusion in his left eye. ICG angiography confirmed the diagnosis of CSCR; there was no obvious neovascularization.

## DISCUSSION

Our study is certainly biased. It is a retrospective study of known CSCR patients who were seen on average 15 years later with subjective complaints. However it certainly suggests that the long-term follow-up of this disease may be poor, due to multiple recurrences inducing diffuse retinal pigment changes and to the occurrence of subretinal neovascularization. The question still remains whether early laser treatment of leaking spots may prevent such an evolution.

Some studies (11, 13) report no further deterioration of vision in the long-term follow-up. Yap et al. (15) reported a long-term visual outcome of 20/25 or better. Others report persistent scotoma as a complication of laser treatment (2, 4).

The aim of laser treatment is to coagulate the leakage points. For some authors (11, 15) direct photocoagulation to the leakage point reduces the frequency of recurrence and shortens the duration. Photocoagulation away from the leak has no influence on the outcome. Laser treatment could reduce the frequency of recurrence (2, 4, 6, 10).

In our study 8 eyes on 11 were treated with laser and the long term visual outcome was poor in 5 of them.

Two of the treated eyes progressed to subretinal neovascularization and the rest progressed to a diffuse pigment epitheliopathy. The subretinal neovascularization in the right eye of case 1 was detected 4 months after laser treatment (13 years after the first attack) and it cannot be excluded that newvessels were already present at the moment of laser treatment.

In case 4 the newvessels appeared 15 years after laser treatment of a leaking spot. The site of newvessels corresponded to that of the previous laser scar. One of the 2 eyes, which had not been treated, progressed towards an atypical epitheliopathy with persistent exudation, the other one developed a choroidal juxtafoveal neovascular membrane.

Subretinal neovascularization appears to be a common complication in older patients with CSCR (1) both in treated (3, 13) and untreated eyes (1, 7). Progression towards a retinal pigment epithelial atrophy, pigment clumping or disciform scar have also been commonly described (15). Pigmentary changes are sometimes indistinguishable with those of ARMD, but the transient choroidal hyperfluorescence observed on indocyaninegreen angiography is of value for distinguishing those 2 aetiologies (8).

In the majority of cases, observable pigment epithelial abnormalities were seen in the fellow eye (9). In 31 % of cases these pigment epithelial abnormalities are the result of asymptomatic macular detachment (9). At follow-up examination new leaks may develop inside and outside areas of previous detachment.

## CONCLUSION

Central serous chorioretinopathy is not necessarily to be considered as a benign disease as in the long run it can progress to diffuse retinal pigmentepitheliopathy or to subretinal neovascularization with eventual loss of central vision. The question remains whether early laser treatment of leakage may prevent further progression or recurrences of the disease. Based on our experience this does not seem to be the case.



## REFERENCES

- (1) BERGER R.A., OLK R.J., BURGESS D. – Central serous choroidopathy in patients over fifty years of age, *Ophthalmic Surg.*, 1991, 22, 583-590.
- (2) BRANCATO R., SCIALDONE A., PECE A., COSCAS G., BINAGHI M. – Eight years follow-up of central serous chorioretinopathy with and without laser treatment. *Graefe's Arch. Clin. Exp. Ophthalmol.*, 1987, 225, 166-168.
- (3) FICKER L., VOFADIS G., WHILE A., LEAVER P. – Long-term results of treatment of CSCR *Trans Ophthalm. Soc. U.K.*, 1986, 105, 473-475.
- (4) FICKER L.A., VOFADIS G., WHILE A., LEAVER P. – Long-term follow-up of a prospective trial of argon laser photocoagulation in the treatment of CSCR, *Br. J. Ophthalmol.*, 1988, 72, 829-834.
- (5) GASS J.D.M. – Pathogenesis of disciform detachment of the neuroepithelium II. Idiopathic central serous choroidopathy. *Am. J. Ophthalmol.*, 1967, 63, 587-615.
- (6) GILBERT C.M., OWENS S.L., SMITH P.D., FINE S.L. – Long-term follow-up of central serous chorioretinopathy, *Br. J. Ophthalmol.*, 1984, 68, 815-820.
- (7) GOMOLIN J.E.S. – Choroidal neovascularization and central serous chorioretinopathy, *Can. J. Ophthalmol.*, 1989, 24, 20-23.
- (8) LAFAUT B.A., DE LAEY J.J. – Indocyanine green angiography in central serous chorioretinopathy, *Bull. Soc. belge Ophtalmol.*, 1996, 262, 55-61.
- (9) LEVINE R., BRUCKER A.J., ROBINSON F. – Long-term follow-up of idiopathic central serous chorioretinopathy by fluorescein angiography, *Ophthalmology*, 1989, 96, 854-859.
- (10) MITCHELL G.C., SARAH L., OWENS S.L., SMITH P.D., FINE S.L. – Long-term follow-up of central serous chorioretinopathy, *Br. J. Ophthalmol.*, 1984, 68, 815-820.
- (11) NANJIANI M. – Long-term follow-up of central serous retinopathy, *Trans Ophthalmol. Soc. U.K.*, 1977, 97, 656-661.
- (12) VON GRAEFE A. – Über centrale recidivierende Retinitis, *Arch. Klin. Ophthalmol.*, 1866, 12, 211-215.
- (13) WATZKE R.C. – Direct and indirect laser photocoagulation of CSCR, *Am. J. Ophthalmol.*, 1979, 88, 914-918.
- (14) YANUZZI L.A., HALL L.S., DAVID G.R. – Central serous chorioretinopathy, *Retina-Vitreous-Macula I*, David G.R., Pennsylvania, 1999, 843, 206-214.
- (15) YAP E.-Y., ROBERTSON D.M. – The long-term outcome of central serous chorioretinopathy, *Arch. Ophthalmol.*, 1996, 114, 689-692.

.....

*Request for reprints to:  
Prof. J.J. De Laey,  
University Eye Hospital,  
De Pintelaan 185,  
B-9000 Ghent,  
Belgium.*









