
IATROGENIC OCULAR VASCULAR OCCLUSIONS: CASE REPORTS

van LINT M. *, DE COCK C. *,
KESTELYN PH. *, DE LAEY J.J. *

SUMMARY

Report of two patients with severe loss of visual acuity after surgery in the head and neck area. Ophthalmic examination and imaging studies demonstrate an occlusion of the ophthalmic and central retinal arteries. In both cases, the underlying physiopathology is the embolisation by an intra-operatively injected substance. Embolisation is thought to occur via anastomosing branches between the external and internal carotid arteries. These cases demonstrate that surgery in head and neck area can result in unexpected and devastating ocular complications.

RÉSUMÉ

Deux patients sont présentés avec une baisse d'acuité visuelle brutale après chirurgie dans la région de la tête et du cou. L'examen ophtalmologique et l'imagerie médicale montrent une occlusion de l'artère ophtalmique et de l'artère centrale de la rétine. Dans les deux cas, la pathophysiologie est une embolisation par une substance injectée durant l'intervention. Les anastomoses entre les artères carotides internes et externes peuvent expliquer cette embolisation. Ces cas montrent que la chirurgie dans la région tête-cou peut résulter dans des complications oculaires imprévues et désastreuses.

SAMENVATTING

In dit artikel bespreken we twee patiënten met een forse visusdaling na heelkunde in de hoofd- en halsregio. Oftalmologisch onderzoek en beeldvorming wijzen op een occlusie van de arteria ophthalmica en de arteria centralis retinae. In beide gevallen bestaat de onderliggende fysiopathologie uit de embolisatie door middel van een intra-operatief geïnjecteerde stof. Deze embolisatie wordt verklaard aan de hand van anastomosen tussen de arteria carotis interna en externa. Deze casussen tonen aan dat heelkunde ter hoogte van hoofd en hals kan resulteren in onverwachte en dramatische oculaire complicaties.

KEY WORDS

Central retinal artery occlusion, ophthalmic artery occlusion, choroidal infarction.

MOTS-CLÉS

Occlusion de l'artère centrale de la rétine, occlusion de l'artère ophtalmique, infarctus choroïdien.

.....

* Dept of Ophthalmology, Ghent University Hospital,
Ghent, Belgium

received: 01.06.06
accepted: 12.07.06

INTRODUCTION

Surgery in the facial area can cause devastating visual complications. In this article we will discuss two cases of visual loss due to vascular occlusion after non-ophthalmic surgery in the facial area.

CASE 1

A 48-year-old female suffers from a severe facial trauma at work. An initial medical examination revealed a nasal deviation and cerebral concussion. Only after two months she is diagnosed with a cerebrospinal fluid fistula with nasal leakage. The fistula persists, despite multiple neurosurgical interventions (January 1998, September 1998, October 1999). Because of the accident and the multiple surgeries, there is a disfiguration of her forehead by scar formation. In order to restore her facial features and in an attempt to close the fistula, a final operation is performed in November 2001, which includes the subcutaneous injection of adipocyte tissue to fill the depressions in the forehead. Apparently there were no peroperative problems.

The patient recovers from the general anesthesia with a left sided hemiplegia.

When the eye patch is removed 2 days after surgery, the patient notes a total loss of vision in the right eye.

Ophthalmic examination only one month later (December 2001) reveals a normal visual acuity of the left eye and no light perception of the right eye. On eye fundus examination, there is optic disc atrophy. The examining ophthalmologist makes the diagnosis of an ophthalmic artery occlusion.

The left sided hemiplegia improved to a less pronounced, though still disabling, hemiparesis.

Imaging studies showed a cerebrovascular accident in the area supplied by the middle cerebral artery, most likely emboligenic in origin. There were also multiple ischemic foci in the watershed area with the posterior and anterior cerebral artery. A cardiovascular examination was unremarkable.

The patient was seen three years later for a medico-legal examination. At that time the visual acuity of the left eye is 10/10 with +1.00 D and no light perception of the right eye. Goldmann visual field is normal for the left eye. Slit lamp examination is normal for the left eye, but shows posterior synechiae in the right eye. Fluorescein angiography demonstrates a primary optic nerve atrophy, attenuated retinal vasculature, retarded filling of the retinal circulation, geographic chorioretinal scar in the macular area, old choroidal infarctions in the temporal periphery and a small area with retinal pigment epithelium alterations infero-temporally (Fig. 1).

These findings are compatible with an ophthalmic artery occlusion with the most likely cause being retrograde embolisation of the injected fat tissue via the internal carotid artery.

CASE 2

A male patient of 47 years suffers from Rendu-Osler-Weber, complicated by recurring nasal haemorrhages. A sclerotizing injection with TissuCol is given in the nasal cavity (Kieselbach's area), resulting in a complete loss of vision of his left eye after a few seconds.

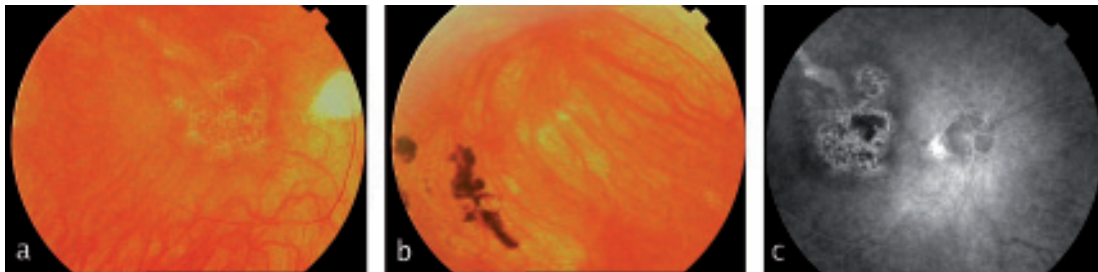


Fig. 1. Case 1. (a) Attenuated arteries, pale optic disc and macular geographic cicatrization. (b) Retinal pigment epithelium alterations infero-temporally. (c) Fluoro-angiography. Macular scar.

An urgent ophthalmic consult is requested. At that moment visual acuity is 10/10 for the right eye and no light perception for the left eye. Eye fundus examination reveals a cherry-red spot and attenuated retinal arteries in the left eye. The patient is treated with dextran 40 (Rheo-macrodex®), dipyridamole (Persantine®) and acetylsalicylic acid (Aspegic®). After one hour the dipyridamole is replaced by nimodipine (Nimotop®). The next day the patient is hardly able to see hand movements. Eye fundus shows less attenuation of the vessels. Two days after the accident the vision of the left eye is hand movements. Visually evoked potentials (VEP) show a decrease in amplitude and increased latencies. On fluorescein angiography, taken 3 days after the accident, the vessels appear to be permeable. The vision did not further improve.

DISCUSSION

The first patient presented an ophthalmic artery occlusion, posterior synechiae, choroidal infarction and sequelae of central retinal artery occlusion. The second patient presented a central retinal artery occlusion. In both cases the vascular accident occurred during surgery.

The visual loss can occur instantaneously after injecting any agent in the head and neck area and there is no associated pain. There were no identifiable risk factors in these patients. There was no recovery of visual function in our cases.

More cases of blindness after different types of surgery in the head and neck region have been reported: embolization in juvenile nasopharyngeal angiofibroma (6), branch retinal artery occlusion following embolization of an intracranial meningioma (8), central retinal artery occlusion following a total laryngectomy (7). Two cases have been reported with a suspicion of CRAO after peribulbar anesthesia possibly induced by a remote effect of the anesthetic agent with vasoconstriction of the central retinal artery (9). This is not an exhaustive enumeration, as more cases have been reported before in the literature.

Surgery in head and neck may result in CRAO by embolisation. To understand the physio-

pathology, the anatomy must be taken into account.

The ophthalmic artery is the first branch of the internal carotid artery. It enters the orbit through the optic canal. Inside the orbit its first branch is the central retinal artery. More distally the short posterior ciliary arteries branch from the ophthalmic artery to supply the choroid.

When a substance is injected under high pressures in head and neck area, it may be forced retrogradely through collaterals and anastomoses between the external and internal carotid artery back into the internal carotid artery, from where the substance can embolize the ophthalmic artery (1).

We believe that this is the mechanism for our cases. Vasoconstriction may be an additional effect of the embolizing agent.

It should be noted that the ophthalmic artery can sometimes originate from the middle meningeal artery. In these cases the ophthalmic artery is at risk in certain neurosurgical procedures and when embolizing branches of the external carotid artery (1,4).

The severity of loss of visual acuity and visual field is determined by the site of the occlusion. If the central retinal artery is occluded, visual acuity can be as low as loss of light perception. If the embolus moves further along the arterial branches, there may still be some visual function, especially if the embolus occludes only a small branch. Macular function can be spared in some cases if there is sufficient cilioretinal perfusion.

The nature of the embolizing agent may influence the prognosis as well. Restoration of the visual acuity has been reported after intratubinate steroid injection with triamcinolone acetonide (5).

The size of the embolus determines how far the embolus can reach in the retinal branches. If the embolus is too large to enter the ophthalmic artery, it may still give rise to neurological consequences.

Treatment consists of attempting to dislodge the embolus and move it further down the artery or its branches. This can be done by ocular massage and preferably by paracentesis.

The visual prognosis is unfavourable and depends on several factors. An additional cilio-

retinal artery may help protect the macular function. Prompt intervention when a CRAO is suspected, is also very important. As the CRAO persists, the visual prognosis becomes worse with time. An experimental study of CRAO in elderly atherosclerotic and hypertensive rhesus monkeys (simulating most patients with CRAO) showed that an occlusion lasting for approximately 240 minutes results in massive, irreversible damage (2,3). The authors conclude that no treatment instituted much longer than 4 hours after loss of vision can logically hope to restore vision.

Follow-up is needed to detect rubeosis iridis in case there are no signs of repermeabilisation on fluorescein angiography. The patient should also have a cardiovascular work-up performed including ultrasound examination of the carotid arteries and heart. Any cardiovascular risk factor must be excluded, e.g. cholesterol emboli (Hollenhorst plaques) and atrial fibrillation. Patients with internal carotid artery stenosis may be asymptomatic (10). Retinal emboli may be accompanied with cerebral emboli. In cases of doubt neurological imaging should be performed as well to rule out a cerebrovascular accident.

CONCLUSION

Surgery in head and neck can result in severe loss of visual acuity, caused by embolization. Associated findings can be contra-lateral neurological manifestations, e.g. hemiplegia. The visual outcome is usually very limited. Therefore, surgery in head and neck must be performed with caution. In case of a CRAO, immediate treatment is mandatory. Even then, however, the prognosis may still be unfavourable.

REFERENCES

- (1) ERNST R.J., BULAS R.V., GASKILL-SHIPLEY M., TOMSICK T.A. – Endovascular Therapy of Intractable Epistaxis Complicated by Carotid Artery Occlusive Disease. *Am J Neuroradiol.* 1995; 16:1463-1468.
- (2) HAYREH S.S., ZIMMERMAN M.B. – Central Retinal Artery Occlusion: Visual Outcome. *Am J Ophthalmol.* 2005; 140:376-391.
- (3) HAYREH S.S., ZIMMERMAN M.B., KIMURA A., SANON A. – Central retinal artery occlusion. Retinal survival time. *Exp Eye Res.* 2004; 78:723-736.
- (4) LIU Q., RHOTON A. – Middle Meningeal Origin of the Ophthalmic Artery. *Neurosurgery.* 2001; 49:401-407.
- (5) MARTIN P.A., CHURCH C.A., PETTI G.H. JR, HEDAYI R. – Visual loss after intratubinate steroid injection. *Otolaryngol Head Neck Surg.* 2003; 128:280-281.
- (6) ÖNERCI M., GUMUS K., CIL B., ELDEM B. – A rare complication of embolization in juvenile nasopharyngeal angiofibroma. *Int J Ped Otorhinolaryngol.* 2005; 69:423-428.
- (7) SMITH W.K., NIXON I., PFLEIDERER A.G. – Central retinal artery occlusion following a total laryngectomy. *J Otolaryngol.* 2004; 33:130-132.
- (8) TURNER T., TROBE J.D., DEVEIKIS J.P. – Sequential Branch Retinal Artery Occlusions Following Embolization of an Intracranial Meningioma. *Arch Ophthalmol.* 2002; 120:857-860
- (9) VINEROVSKY A., RATH E.Z., REHANY U., RUMELT S. – Central retinal artery occlusion after peribulbar anesthesia. *J Cat Refr Surg.* 2004; 30:913-915.
- (10) WIJMAN C., GOMES J.A., WINTER M.R., KOLEINI B., MATJUCHA M., POCHAY V.E., BABIKIAN V.L. – Symptomatic and Asymptomatic Retinal Embolism Have Different Mechanisms. *Stroke.* 2004; 35:100-102.

.....

Correspondence and reprints

Michel van LINT
 UZ-Gent / Oftalmologie / Poli 1
 De Pintelaan 185
 B-9000 Gent - Belgium
 E-mail: m_van_lint@hotmail.com