THE USE OF INTRAVITREAL BEVACIZUMAB IN NEOVASCULAR GLAUCOMA: A CASE REPORT

KELKAR A.S., KELKAR S.B.*,*
KELKAR J.A., NAGPAL M.**, PATIL S.P. **

SUMMARY:

Purpose: To assess the short-term safety and efficacy of an intravitreal injection of bevacizumab in a patient with neovascular glaucoma.

Case report: Intravitreal bevacizumab injection was given in a patient with neovascular glaucoma and the changes in the visual acuity, intraocular pressure (IOP), iris neovascularisation were noted before injection and after one day, one week, three weeks and six weeks.

Regression of the iris new vessels and normalization of the intraocular pressure was noted.

Conclusion: Intravitreal bevacizumab was effective and safe in the short-term in a patient with neovascular glaucoma. It may be a useful adjunctive treatment.

RÉSUMÉ:

But: Etablir l'efficacité et l'innocuité à court terme d'une injection intravitréenne de Bevacizumab dans le glaucome néovasculaire.

Méthode et résultats: Une injection intravitréenne de Bevacizumab a été effectuée chez un patient présentant un glaucome néovasculaire. L'évolution de la vision, de la tension intra-oculaire et de la néovascularisation irienne a été suivie avant l'injection, et un jour, une semaine, trois semaines et six semaines après l'injection. Nous avons noté une régression de la néovascularisation irienne et une normalisation de la tension intra-oculaire.

Conclusion: Cette observation indique que l'injection de Bevacizumab est possible et efficace à court terme chez des patients atteints de glaucome néovasculaire. Ceci peut être un traitement d'appoint fort utile.

SAMENVATTING:

Doelstelling: Nagaan van de efficientie en de veiligheid op korte termijn van een intravitreale inspuiting van Bevacizumab bij neovasculair glaucoom.

Methode en resultaten: Een patient met neovasculair glaucoom werd behandeld met een intravitreale inspuiting van Bevacizumab. De evolutie van visus, oogdruk en iris neovascularisatie werd gevolgd, voor de inspuiting en één dag, één week drie weken en zes weken na de inspuiting. Regressie van de neovascularisatie van de iris en normalisatie van de oogdruk werden waargenomen.

Besluit: Dit geval wijst op de veiligheid en de doeltreffendheid op korte termijn van Bevacizumab inspuitingen in ogen met neovasculair glaucoom. Deze inspuiting kan een nuttige aanvulling zijn bij de behandeling van het neovasculair glaucoom.

KEY WORDS:

Neovascular glaucoma, intravitreal bevacizumab.

MOTS-CLÉS:

Glaucome néovasculaire, injection intravitréenne de Bevacizumab

.....

** National Institute of Ophthalmology, Pune, India.*
*** Retina Foundation, Ahmedabad, India.*

received: 18.08.06
accepted: 26.10.06

INTRODUCTION:

Vascular endothelial growth factor (VEGF) is an endothelial cell-specific mitogen in vitro and an angiogenic inducer in a variety of in vivo models. Hypoxia has been shown to be a major inducer of VEGF gene transcription.[1]
Bevacizumab (Avastin®, Genentech, San Francisco, CA, USA) is a recombinant humanized monoclonal IgG1 antibody that inhibits human vascular endothelial growth factor (VEGF). It has been approved by the Food and Drug Administration as a first-line treatment for metastatic colorectal cancer in combination with chemotherapy[1]. It has been administered intravitreally in VEGF mediated diseases such as choroidal neovascularisation[4], central retinal vein occlusion[5] and neovascular glaucoma[3]. The Tübingen Bevacizumab study has also demonstrated the usefulness of intracameral injection of Bevacizumab in neovascular glaucoma[2]. We describe a patient who had a dramatic regression of the iris neovascularisation following intravitreal Bevacizumab injection.

CASE REPORT:

A 65-year old non-insulin dependent diabetic and hypertensive male patient presented with neovascular glaucoma in the left eye. The patient was a known case of glaucoma since seven years and was on antiglaucoma treatment for the last seven years. The patient had undergone trabeculectomy one year previously due to uncontrolled intraocular pressure.
On presentation the visual acuity in the left eye was light perception and projection of rays in all four quadrants and the intraocular pressure was 38 mm Hg under topical and systemic antiglaucoma medication. The anterior segment examination revealed corneal edema, neovascularisation of the iris, posterior synechiae, a shallow anterior chamber, a dense cataract (Fig 1) and no reflective glow on fundus examination. On Ultrasound B scan, the retina was attached and there was mild vitreous haze. Gonioscopy was deferred due to the presence of corneal edema.
The anterior segment examination of the right eye showed early cataract and the fundus examination was normal. The visual acuity was 6/6 and the IOP was 13 mm Hg.

Fig. 1

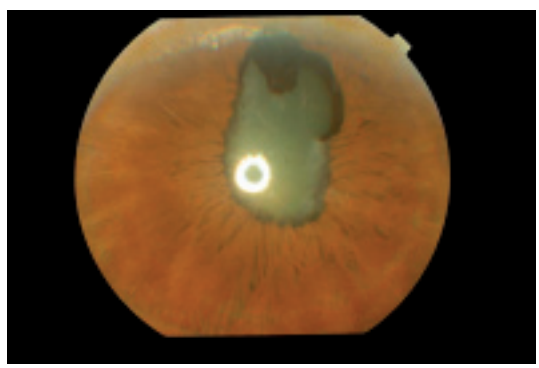

Fig. 2

The patient was put on intravenous 20% mannitol - 100 cc once a day, a tablet of acetazolamide 250 mg twice a day, topical betaxolol eye drops 2 times a day together with steroid antibiotic eye drops 4 times a day for two days to control the intraocular pressure. The intraocular pressure was brought under control and gonioscopy was performed. Gonioscopy showed the presence of anterior synechiae and neovascularisation in the angle. Since the anterior chamber was shallow, in order to avoid damage to the anterior lens capsule, an intravitreal injection of Bevacizumab (Avastin®) - 0.05cc (1.25mg) was performed in the operation room using all aseptic precautions:

- 5% betadine eye drops were instilled half an hour before the procedure.
- topical 0.5% proparacaine drops were instilled.
- 0.05 cc Bevacizumab was taken in a tuberculin syringe with 26 g needle.

- using a caliper, a distance of 4 mm from the limbus was marked and 0.05 cc Bevacizumab was injected.
- The eye was padded and a tablet acetazolamide 250 mg given immediately after the procedure.

On the first day after the injection, the IOP was 18 mm Hg in the treated eye. The cornea was clear, the iris new vessels showed some regression and the patient was symptomatically better. The antiglaucoma treatment was stopped and the patient was discharged. On the fourth day, the IOP was 10 mm Hg and the new vessels showed further regression. On the seventh day, there was a near total regression of the new vessels on the iris and angle structures and the IOP was 10 mm Hg without any medication. At 3 weeks follow-up (Fig 2) there was total regression of the iris new vessels and the IOP remained at 10 mm Hg. At 6 weeks follow-up, there was no evidence of the new vessels on the iris or in the angles and the IOP was 14 mm Hg. Gonioscopy revealed no evidence of new vessels in the angle of anterior chamber. However, the visual acuity did not improve, possibly due to the preexisting optic nerve damage. Fundus details were not visible due to the dense cataract.

DISCUSSION:

This case illustrates the short-term usefulness of an intravitreal Bevacizumab (Avastin ®) in a diabetic and hypertensive patient with neovascular glaucoma (following a previous failed trabeculectomy). The procedure resulted in rapid improvement of symptoms, IOP control and complete regression of the new vessels within one week. No complications were observed within six weeks. The procedure can be a useful adjunctive in the treatment for neovascular glaucoma. A larger randomized clinical study with longer follow-up is needed to conclude on the efficacy and safety in the long run. It is possible that the effects of treatment may be short lasting and patients may require repeated injections. However, present results seem gratifying and may offer new hope for such conditions.

REFERENCES:

(1) FERRARA N. – Vascular endothelial growth factor: basic science and clinical progress Endocr Rev. 2004; 25:581-611

(2) GRISANTI S., BIESTER S., PETER S., TATAR O., ZIEMSSEN F., BARTZ-SCHMIDT K.U.; – Tübingen Bevacizumab Study Group. Intracameral bevacizumab for iris rubeosis. Am J Ophthalmol 2006; 142:158-60

(3) KAHOOK M.Y., SCHUMAN J.S., NOECKER R.J.. – Intravitreal bevacizumab in a patient with neovascular glaucoma. Ophthalmic Surg Lasers Imaging 2006; 37:144-6

(4) ROSENFELD P.J., MOSHFEGHI A.A., PULIAFITO C.A. – Optical coherence tomography findings after an intravitreal injection of bevacizumab (avastin) for neovascular age-related macular degeneration. Ophthalmic Surg Lasers Imaging 2005; 36:331-335

(5) ROSENFELD P.J., FUNG A.E., PULIAFITO C.A., – Optical coherence tomography findings after an intravitreal injection of bevacizumab (avastin) for macular edema from central vein occlusion. Ophthalmic Surg Lasers Imaging 2005; 36:336-339

.....

Address for correspondence:

Dr Aditya KELKAR
National Institute of Ophthalmology
1187/30 Off Ghole road,Shivajinagar
Pune 411005
Tel Nos 00912025536369/24
Fax no:00912025534572
e-mail: drjkelkar@yahoo.com