CHOROIDAL NEOVASCULARIZATION FOLLOWING PHOTODYNAMIC THERAPY IN A PATIENT WITH CHRONIC CENTRAL SEROUS CHORIORETINOPATHY

YAMAN A.[1], ARIKAN G.[1], SAATCI A.O.[2], CINGIL G.[2]

ABSTRACT

Purpose: To present the clinical features and treatment of subfoveal choroidal neovascularization complicating photodynamic treatment (PDT) performed for chronic central serous chorioretinopathy (CSC).
Method: A 48-year-old healthy woman who had chronic visual deterioration in her right eye due to chronic CSC was treated with standard PDT protocol.
Results: Three weeks after the initial PDT, she experienced recovery in her vision and neurosensory detachment subsided clinically. However , six weeks after the PDT she returned with decreased visual acuity and metamorphopsia in the right eye. Fluorescein angiogram and optic coherence tomography delineated a classic subfoveal subretinal neovascular membrane. PDT was reperformed two more times, three months apart and closure of neovascular membrane was obtained.
Conclusion: Choroidal neovascularization might have occurred during the natural course of disease process or as a consequence of PDT. PDT seems to be effective for treating the choroidal neovascularization complicating PDT performed for CSC.

RÉSUMÉ

Objectif: Un cas de chorioréthinopathie séreuse centrale (CRSC) chronique ayant montré une néovascularisation choroïdienne subfovéolaire après thérapie photodynamique (PDT) est rapporté. La particularité clinique et l'attitude thérapeutique sont discutées.
Patient et méthode: Il s'agit d'une femme de 48 ans, qui a consulté pour une baisse d'acuité visuelle de l'oeil droit, liée à une CRSC chronique et qui a été traitée suivant le protocole standard PDT.
Résultats: Trois semaines après la première application de PDT, on a constaté une augmentation de l'acuité visuelle et une amélioration du décollement séreux rétinien. Six semaines plus tard cependant la patiente s'est présentée de nouveau pour une baisse de l'acuité visuelle et de métamorphopsie. L'angiographie à la fluorescéine et la tomographie en cohérence optique (OCT) ont montré la formation d'une membrane néovasculaire sous-rétinienne. Deux séances de retraitement suivant le PDT à trois mois d'intervalle, ont été suivies d'une diminution de la réaction exudative et d'une réapplication de la rétine.
Conclusions: La néovascularisation choroïdienne peut se développer au cours de l'évolution naturelle de la CRSC ou peut être induite par PDT. D'autre part, bien qu'il soit compliqué par une néovascularisation choroïdienne, le PDT semble être un traitement efficace pour CRSC.

KEY WORDS:

central serous chorioretinopathy, fluorescein angiography, indocyanine green angiography, optic coherence tomography, photodynamic therapy, subretinal neovascular membrane.

MOTS-CLÉS:

choriorétinopathie séreuse centrale, angiographie à la fluorescéine, angiographie en vert d'indocyanine, tomographie en cohérence optique, thérapie photodynamique, membrane néovasculaire sous-rétinienne.

.....

[1] *Fellow,Department of Ophthalmology, Dokuz Eylul University, Izmir, Turkey*
[2] *Professor, Department of Ophthalmology, Dokuz Eylul University, Izmir, Turkey*

received: 31.10.06
accepted: 12.01.07

INTRODUCTION

Central serous chorioretinopathy (CSC) can be defined as the idiopathic detachment of the neurosensory macula with a focal leak at the level of retinal pigment epithelium (RPE) with fluorescein angiography (FA). Unifocal neurosensory detachment involving the central macula for at least six months or multifocal recurrent detachments with diffuse decompensation of the RPE and gradual indistinct RPE leakage on FA can be termed as chronic CSC (11). Patients with chronic CSC have a guarded visual prognosis as prolonged macular detachment may lead to irreversible structural changes within the neurosensory retina and therefore chronic CSC may warrant treatment. Several authors reported a beneficial outcome with verteporfin photodynamic treatment (PDT) in cases with chronic CSC (2,6,8,10,11). It is also speculated that subretinal neovascular membrane formation is not increased with PDT when compared to thermal laser photocoagulation in eyes with chronic CSC and PDT can be applied earlier after the onset of visual symptoms (1).

We hereby report a patient who developed subfoveal classic subretinal neovascular membrane after PDT for chronic CSC. The subretinal neovascular membrane was treated again two more times with PDT.

CASE REPORT

A 48-year-old otherwise healthy woman had a history of visual loss in her right eye of at least two months duration. Her best-corrected visual acuity was 20/50 in the right eye and 20/25 in the left eye. Bilaterally, slit-lamp examination was unremarkable. Fundus examination, FA and optic coherence tomography (OCT) revealed the presence of serous retinal detachment at the posterior pole and there were at least two pinpoint foveal leaks in OD (Figures 1 a,b and c). Left fundus was normal. Our diagnosis was right CSC and we did not treat her at that time. She returned ten months later stating that her visual acuity did not improve. On examination, her best-corrected visual acuity was 20/50 in OD. Contact lens biomicroscopy disclosed a persistent neurosensory retinal detachment. FA showed that multiple leakage sites were present (Figures 2a and b). However, indocyanine green angiogram and OCT were not performed. We diagnosed the case as chronic CSC. This time, the patient demanded a treat-

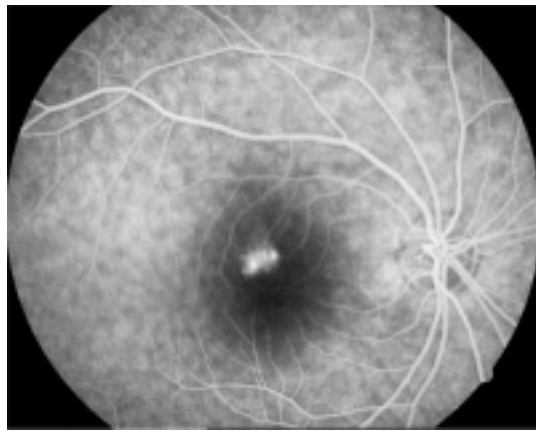

Figure 1a. Right eye, Venous phase of fluorescein angiogram showing two foveal focal leaks.

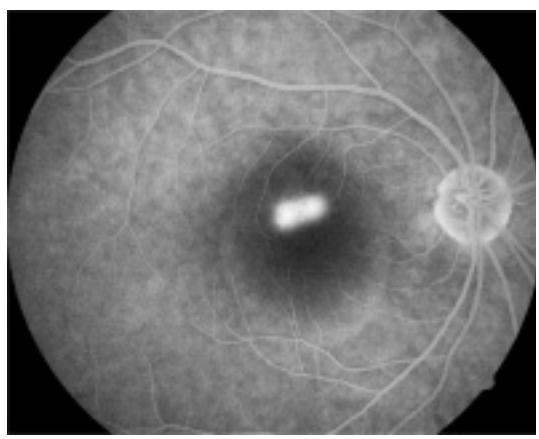

Figure 1b. Right eye, Late venous phase, Progressive leakage of the focal leaks.

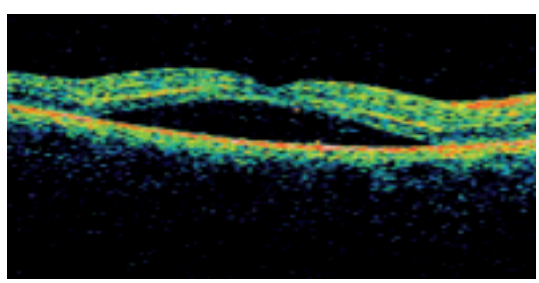

Figure 1c. Right eye, Optic coherence tomogram demonstrating the neurosensory retinal detachment.

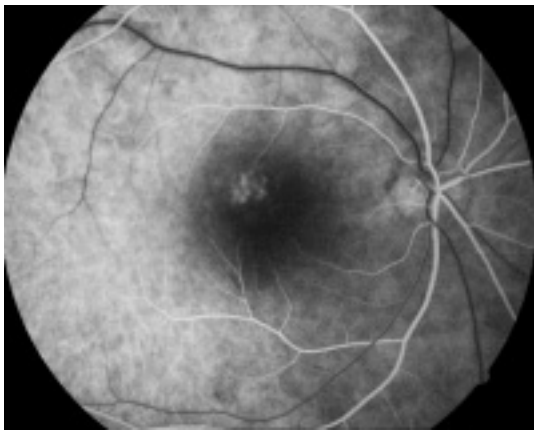

Figure 2a. Right eye, Early arteriovenous phase showing multiple leaking sites.

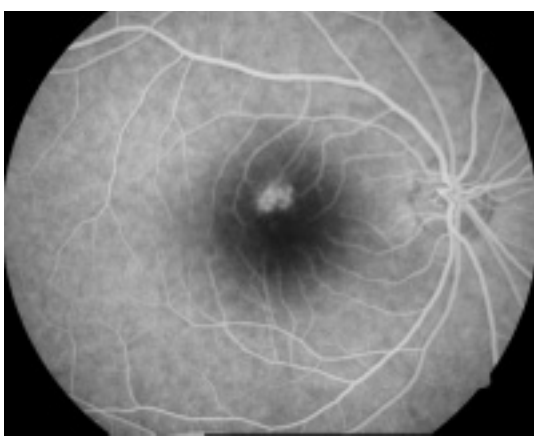

Figure 2b. Right eye, Venous phase showing increase in leakage.

ment and we offered her PDT. After receiving informed consent, intravenous verteporfin (6mg/ m^2) (Visudyne, Novartis AG, Basel, Switzerland) was administered over a 10 minute period. Five minutes after the completion of infusion, laser was delivered at an intensity of 600 mw/ cm^2 for 83 seconds using a Goldmann three-mirror contact lens. The spot size was 1500 μm and we aimed to cover the leakage sites altogether with a safety margin. Three weeks later, her best-corrected visual acuity was 20/25 and biomicroscopically the neurosensory detachment vanished. Six weeks after the PDT she came back with decreased visual acuity and metamorphopsia in her right eye. FA and OCT were obtained and a classic subfoveal choroidal neovascular membrane was detected (Figure 3a,b and c). We reperformed the PDT with a spot size of 2000 μm. The mem-

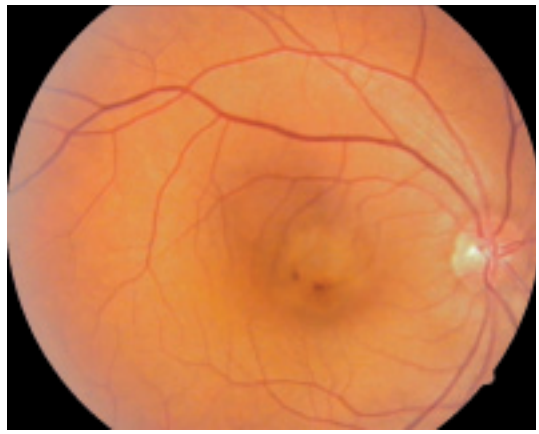

Figure 3a. Right eye, Color fundus picture delineating two small intraretinal hemorhages indicating the presence of subretinal neovascular membrane.

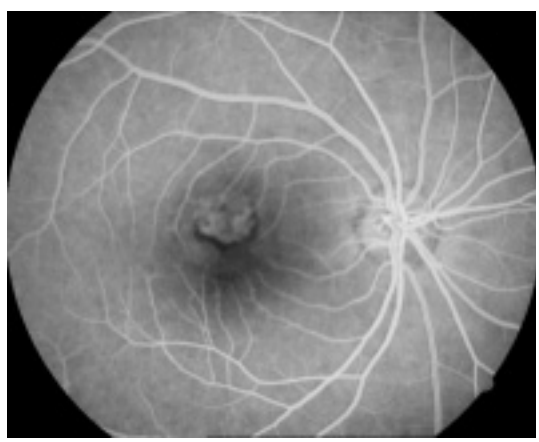

Figure 3b. Right eye, Venous phase of fluorescein angiogram showing classic subfoveal subretinal neovascular membrane.

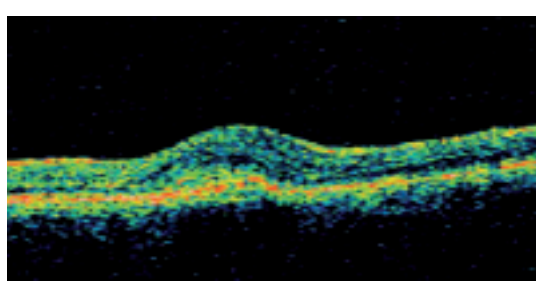

Figure 3c. Right eye, Optic coherence tomogram showing the subretinal neovascular membrane with subtle sensorial retinal edema.

Table: *outcome of photodynamic treatment in eyes with chronic central serous chorioretinopathy*

authors (year)	number of eyes/number of patients	mean age (years)	resolution of fluid	mean follow-up (months)	complication
Piccolino et al (6) 2003	16/16	59	Total 13/16 Partial 3/16	11.2	Recurrence 2/16 RPE changes 5/16
Chan et al (2) 2003	6/6	44.8	6/6	12.7	Subretinal neovascular membrane 1/16
Yannuzzi et al (11) 2003	20/15	60	Total 12/20 Partial 8/20	6.8	None
Taban et al (8) 2004	5/4	58.5	5/5	10	None
Valmaggia et al (10) 2006	14/13	48.2	14/14	1	None

brane was closed angiographically two weeks after the second PDT (Figure 4). We retreated her again with PDT three months later as she noticed slight decrease in her vision and the membrane seemed active angiographically.

DISCUSSION

CSC is recognized as a benign disease with a generally favorable outcome and most often resolves spontaneously in four to six months. Factors associated with reduced visual acuity during the long-term follow-up of patients with idiopathic CSC include persistent pigment epithelial detachment and/or subretinal fluid, recurrences and submacular choroidal neovascularization (4).

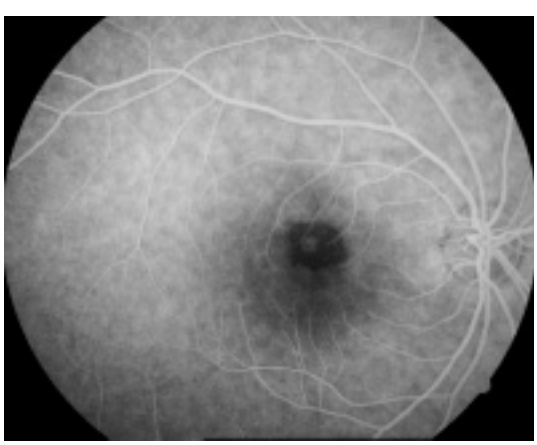

Figure 4. Right eye, Almost total closure of classic subretinal neovascular membrane following the photodynamic treatment.

Recently, several studies recommended PDT for chronic CSC and reported promising results (Table). Preferred treatment protocol was the same as the protocol used for wet-type age related macular degeneration (9). However, authors placed the laser spot or spots in different ways. Some authors cover the focal leakage area or areas identified by FA with a single or more spots or cover the area of diffuse leakage with a single spot (1,3,8,10). Others cover the areas of choroidal abnormality such as dilated and congested choroidal vessels and the area within sub-RPE extravascular leakage in the macula according to indocyanine green angiographic findings (2,5,6,11).

Several theories were considered to explain the favorable outcome after PDT in cases with CSC. Temporary choriocapillaris occlusion and endothelial changes occur following the PDT and this might reduce the vascular permeability and decrease fluid passage toward the retina (5,6). Moreover, RPE cells damaged by light-activated verteporfin might be replaced by new ones with possible recovery from the metabolic impairment at the RPE level (5,7).

So far, two eyes were reported to develop choroidal neovascularization after PDT for chronic CSC. Chan et al. (2) reported a 48-year-old patient with chronic diffuse leakage who developed a juxtafoveal subretinal neovascular membrane at three month follow-up visit despite good response to indocyanine green angiography guided PDT. No further treatment was performed. More recently, Coluciello (3) described a 63-year-old man with recurrent CSC who un-

derwent a single session of PDT. The pre-PDT fluorescein angiogram demonstrated two pinpoint focal leaks. Neurosensory retinal detachment resolved completely three weeks after the treatment. The patient experienced visual deterioration three months later and a classic subfoveal subretinal neovascular membrane was noted. The patient was not treated as the author believed that further treatment was unnecessary due to lack of subretinal fluid or macular edema.

Choroidal neovascularization was reported in 2% of 101 eyes with CSC followed-up for more than three years without any treatment (4). Choroidal neovascularization may occur during the natural disease course. On the other hand, it is well possible that PDT may induce choroidal neovascularization in eyes with CSC. Theoretically, PDT causes choriocapillaris closure and consequently induces ischemia leading to upregulation of VEGF in regions where PDT is applied (2,3). As a result, an angiogenic impulse may arise.

When we reviewed the clinical course of our patient it was possible that the membrane might have been present prior to PDT. In light of this assumption, we believe that OCT and indocyanine green angiography should be mandatory in every case of CSC. Moreover, further studies are necessary to determine the ideal PDT parameters and elucidate risk factors for PDT induced choroid neovascularization in eyes with chronic CSC .

REFERENCES

(1) CANAKIS C., LIVIR-RALLATUS C., PANAYIOTIS Z., LIVIR-RALLATUS G., PERSIDIS E., CONWAY M.D., PEYMAN G.A. – Ocular photodynamic therapy for serous macular detachment in the diffuse retinal pigment epitheliopathy variant of idiopathic central serous chorioretinopathy. Am J Ophthalmol 2003; 136: 750-752.

(2) CHAN W., LAM D.S.C., LAI T.Y.Y.,TAM B.S., LIU D.T., CHAN C.K. – Choroidal vascular remodelling in central serous chorioretinopathy after indocyanine green guided photodynamic therapy with verteporfin: A new treatment at the primary disease level. Br J Ophthalmol 2003;87: 1453-1458.

(3) COLUCCIELLO M. – Choroidal neovascularization complicating photodynamic therapy for central serous retinopathy. Retina 2006; 26:239-42.

(4) LOO R.H., SCOTT I.U., FLYNN JR H.W., GASS J.D.M., MURRAY T.G., LEWIS M,L,. ROSENFELD P.J., SMIDDY W.E. – Factors associated with reduced visual acuity during long-term follow-up of patients with idiopathic central serous chorioretinopathy. Retina 2002;22:19-24.

(5) PARODI M.B., DA POZZO S., RAVALICO G. – Photodynamic therapy in chronic central serous chorioretinopathy. Retina 2003; 23: 235-237.

(6) PICCOLINO F.C., EANDI C.M., VENTRE L., RIGAULT DE LA LONGRAIS R.C., GRIGNOLO F.M. – Photodynamic therapy for chronic central serous chorioretinopathy. Retina 2003; 23:752-63.

(7) SCHMIDT-ERFURTH U., HASAN T. – Mechanism of action of photodynamic therapy with verteporfin for the treatment of age-related macular degeneration. Surv Ophthalmol 2000;45: 195-214.

(8) TABAN M., BOYER D.S., THOMAS E.L., TABAN M. – Chronic central serous chorioretinopathy: Photodynamic therapy. Am J Ophthalmol 2004; 137: 1073-1080.

(9) TREATMENT OF AGE- RELATED MACULAR DEGENERATION WITH PHOTODYNAMIC THERAPY (TAP) STUDY GROUP: Photodynamic therapy of subfoveal choroidal neovascularization in age related macular degeneration with verteporfin:one-year results of 2 randomized clinical trials. TAP report 1. Arch Ophthalmol 1999; 117: 1329-45.

(10) VALMAGGIA C., NIEDERBERGER H. – Photodynamic treatment of chronic central serous chorioretinopathy. Klin Monatsbl Augenheilkd 2006;223:372-375.

(11) YANUZZI L.A., SLAKTER J.S., GROSS N.E., SPAIDE R.F., COSTA D.L., HUANG S.C., KLANCNIK C.E. JR., AIZMAN A. – Indocyanine green angiography-guided photodynamic therapy for treatment of chronic central serous chorioretinopathy. A pilot study. Retina 2003; 23: 288-98.

.....

Address for correspondance and reprints:

Prof A. Osman SAATCI
Mustafa Kemal Sahil Bulvari
No:73, A Blok, Daire:9
Narlıdere, Izmir, 35320
Turkey
Fax:90 232 2782717
e-mail: osman.saatci@yahoo.com
osman.saatci@deu.edu.tr