
PERIPHERAL EXUDATIVE AND HEMORRHAGIC CHORIO-RETINOPATHY ... THE PERIPHERAL FORM OF AGE-RELATED MACULAR DEGENERATION? REPORT ON 2 CASES.

*COLLAER N. *, JAMES C. **

SUMMARY

Report of two patients presenting with peripheral exudative hemorrhagic chorioretinopathy, an under-recognized, possible sight-threatening condition. Thorough examination of the peripheral fundus remains the key factor in recognizing this disease. The greatest immediate risk for the patient is an incorrect diagnosis of suspected choroidal melanoma.

KEY WORDS

Peripheral exudative hemorrhagic chorioretinopathy.

MOTS-CLÉS

Chorio-rétinopathie périphérique exsudative et hémorragique.

SAMENVATTING

In dit artikel bespreken we twee patiënten met perifere exudatieve hemorrhagische chorioretinopathie, een weinig erkende en potentieel visus bedreigende aandoening. Perifeer oogfundusonderzoek is prioritair bij de diagnose van deze ziekte. Het grootste gevaar bestaat in een verkeerde diagnose van choroïdaal malign melanoom.

RÉSUMÉ

Deux patients se sont présentés avec une chorio-rétinopathie périphérique exsudative et hémorragique, une affection sous-estimée et susceptible de provoquer une cécité. Un examen approfondi du fond d'oeil est essentiel pour identifier cette affection. Le danger consiste à poser le diagnostic erroné de mélanome choroïdien.

.....

* *Tobay Hospital, Department of Ophthalmology, Torquay, UK*

received: 01.02.07

accepted: 17.04.07

INTRODUCTION

Age-related macular degeneration is an ongoing point of interest in ophthalmology as it is a serious sight-threatening condition for which anti-VEGF treatment offers fresh hope.

By contrast, peripheral disciform lesions have received much less attention in the ophthalmic literature. Whether this lack of reports is the result of factors like unsatisfactory clinical examination of the peripheral fundus due to the asymptomatic nature of the disease in the early stages, or the truly low incidence of the condition is unknown. Unfortunately, as the following two cases outline, this disease can also be sight-threatening.

CASE 1

An 87-year old man, a known hypertensive, first presented with 6/18 vision in the left eye due to a vitreous haemorrhage of unknown origin. When this failed to clear he underwent a vitrectomy and an inferotemporal subretinal hemorrhagic process was found to be the causative factor. He was discharged in 2000 with an attached retina with inferotemporal scarring and a visual acuity 6/4, only to represent again in 2006 with a left acute temporal field defect in association with a superonasal subretinal haemorrhage (Figure 1). Conservative management resulted in clearing of the subretinal haemorrhage.

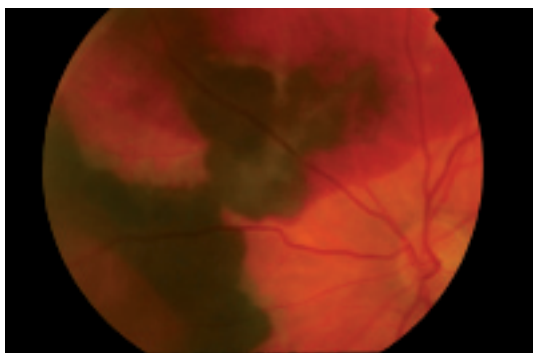


Fig. 1 Superonasal quadrant left eye showing extensive subretinal blood.

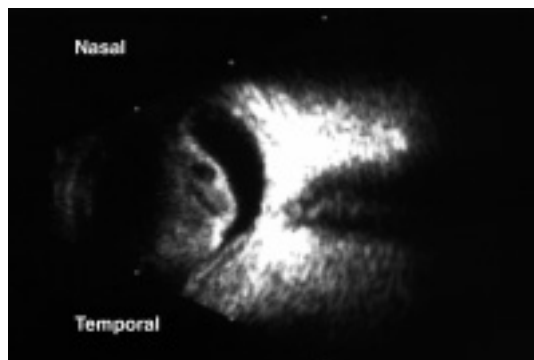


Fig. 2 Ultrasound right eye, horizontal section, showing dense vitreous haemorrhage and choroidal elevation involving macula.

CASE 2

A 62-year old hypertensive, diabetic man on Aspirin, with diabetic retinopathy which had previously been treated with right panretinal photocoagulation (2000) and bilateral focal laser treatment (2002). In 2004 an inferotemporal peripheral lesion with subretinal haemorrhage and exudates was detected in the right eye. Visual acuity at that stage was 6/12 in the right eye. Ten months later he represented with a sudden loss of vision due to a massive spontaneous subretinal haemorrhage in the periphery (360°) which extended to involve the macula, with breakthrough vitreous haemorrhage. No visual recovery occurred. (Figure 2.)

DISCUSSION

TERMINOLOGY

Reviewing the literature on the terminology used to describe peripheral disciform lesions is confusing. Different names (1,4,7,8,10) have been given to similar lesions in various locations and stages of evolution. Peripheral exudative hemorrhagic chorioretinopathy (PEHCR) introduced by Annesley (1) in his 1980 extensive review article and subsequently used by Shields (7), has become the chosen descriptive term for this condition. Annesley introduced this term to define chorioretinal lesions characterized by blood, either subretinal, or subretinal pigment epithelial, or both, and by exudates. All the lesions were located anterior to the equator.

ETIOLOGY

The cause of the abnormal growth of peripheral subretinal new vessels remains speculative. Ischemia has traditionally been considered to be the stimulus for neovascularization. The posterior part of the pars plana, the ora serrata and the pre-equatorial region comprise a uveal vascular watershed. In addition, the peripheral retina has a sparse vascular supply, and is therefore a region of selective vulnerability. These circumstances may be further aggravated by potentially ischemic systemic conditions such as diabetes mellitus and raised blood pressure (2). Secondly mechanical forces induced by vitreoretinal traction within the vitreous base, or shearing forces related to accommodation, might play a causative or aggravative role (2). Finally the possibility of a defect in Bruch's membrane acting as a predisposing factor is considered (2). Although many conditions associated with choroidal neovascularization have breaks in Bruch's membrane as a common feature, histopathologically the importance of these breaks in this peripheral condition is not clear (2,3,5,6,9).

The origin of the peripheral subretinal neovascularization is unclear. Several authors report on an extra vascular network in the inner collagenous layer of Bruch's membrane at the ora serrata in autopsy eyes as a common feature; but without agreement on a possible pathological nature of these vessels. (2,3,5,6,9). Whether the causative vascular net of PEHCR is a subretinal neovascular membrane of choroidal origin, as seen in age-related macular degeneration, or a peripheral subretinal vessel present in the inner collagenous layer of Bruch's membrane, remains an open question ...

DIAGNOSIS

Many reports emphasize the vascular nature of the lesions, resulting in hemorrhagic detachments of the retinal pigment epithelium or extensive areas of peripheral subretinal exudation. Fundus examination with indirect ophthalmoscopy and scleral depression is the best means of confirming the diagnosis. Unfortunately, the presence of vitreous haemorrhage may obscure the fundus view, and ultrasonography may be helpful when the retina cannot

Table 1: *Peripheral chorioretinal lesions: exudative*

Choroidal detachment
Uveal effusion syndrome
Choroidal haemangioma
Inflammatory subretinal granulomas
Organized snow banks in pars planitis
Collections of subretinal exudates from retinal vascular disorders (retinal capillary haemangioma, retinal telangiectasia, familial exudative vitreo-retinopathy (FEVR))

be visualized. In a review of 12,000 patients referred for suspected posterior uveal malignant melanoma Shields (7) reported that 1739 (14%) were found to have a simulating lesion. The second most frequent condition, after choroidal nevus, was PEHCR accounting for 139 cases (8%). Clinical findings and ultrasonography, fluorescein angiography and indocyanine green angiography and radioactive phosphorus uptake test were suggested to help establish the diagnosis. A number of conditions can resemble this disorder in one of its stages, and a summary of the more important diseases in the differential diagnosis is given in Tables 1-2; of these, malignant choroidal melanoma is the most important.

MANAGEMENT

The first important aspect of the management of PEHCR is recognition of this entity. Because extensive haemorrhage often obscures the location of the underlying peripheral subretinal neovascularization, and because the haemorrhages seem to resorb relatively rapidly, conservative treatment is often appropriate. However, visual prognosis is poor once central vision is impaired. The value of preventing visual loss by photocoagulation or cryotherapy in patients with documented peripheral subretinal neovascularization has not been deter-

Table 2. *Peripheral chorioretinal lesions: mixed hemorrhagic-exudative*

Retinal arterial macro-aneurysm
Retinal telangiectasia
Retinal capillary haemangioma
Polypoidal choroidopathy
Haemorrhage into retinoschisis
Malignant melanoma of the choroid

mined. It might be beneficial if peripheral vascular nets could be identified prior to the haemorrhage. In their study of autopsy eyes, Foos and Trese (2) found an association of cardiovascular disease in patients with peripheral subretinal neovascularization. There have been a number of case reports of massive subretinal haemorrhages in patients with central disciform macular degeneration who were given anticoagulants. The authors of this article have seen massive, blinding, subretinal haemorrhage from peripheral neovascular membranes in patients with peripheral exudative hemorrhagic chorioretinopathy. Therefore, a thorough history for the presence of hypertension, arteriosclerosis and anticoagulative drugs is mandatory. Normalization of blood pressure is advisable and discontinuation or at least a reduction of anticoagulant therapy, if medically acceptable, may need to be considered.

A detailed examination of the peripheral fundus also needs to be part of any preoperative assessment for intraocular surgery, because of the increased risk of peroperative suprachoroidal haemorrhage or postoperative deterioration secondary to an exudative reaction.

CONCLUSION

Peripheral exudative hemorrhagic chorioretinopathy may be more common than is generally thought and can lead to temporary or permanent loss of sight in its more advanced stages. This condition should be kept in mind during dilated fundus examination of the far periphery for any patient presenting with posterior segment symptoms. The most important messages are not to mistake this condition for choroidal malignant melanoma, and to consider the anticoagulative status of the patient if active disease is identified, as there is a risk of massive subretinal haemorrhage. It will be interesting to see if anti-VEGF therapy becomes an effective treatment for this sight threatening condition.

Based on a review article which first appeared in Eye News 2007;13:6-12 with kind permission of Pinpoint Scotland Ltd.

REFERENCES

- (1) ANNESLEY W. – Peripheral exudative hemorrhagic chorioretinopathy. *Trans Am Ophthalmol Soc* 1980;87:518-522.
- (2) FOOS R.Y, TRESE M.T. – Chorioretinal juncture. Vascularization of Bruch's membrane in peripheral fundus. *Arch Ophthalmol* 1982; 100:1492-1503.
- (3) FRIEDMAN E., SMITH T.R., KURWABANA T. – Senile Choroidal Vascular Patterns and Drusen. *Arch Ophthalmol* 1963;69:220-230.
- (4) GASS J.D.M. – Stereoscopic Atlas of Macular Diseases: A Fundoscopic and Angiographic Presentation, 4th ed. St Louis CV Mosby, 1997;248-250.
- (5) RING H.G., FUJINO R. – Observations on the Anatomy and Pathology of the Choroidal Vasculature. *Arch Ophthalmol* 1967;78:431-444.
- (6) SARCS S.H. – New vessel formation beneath the retinal pigment epithelium in senile eyes. *Br J Ophthalmol* 1973;57:951-965.
- (7) SHIELDS J.A., MASHAYEKHI A., RA S., SHIELDS C.L. – Pseudomelanomas of the posterior uveal tract. *Retina* 2005;25:767-771.
- (8) SILVA V.B., BROCKHURST R.J. – Hemorrhagic detachment of the peripheral retinal pigment epithelium. *Arch Ophthalmol* 1976;94:1295-1300.
- (9) SPITZNAS M., BORNFIELD N. – The architecture of the most peripheral retinal vessels. *Albrecht Von Graefes Arch Klin Exp Ophthalmol* 1977;203:217-229.
- (10) VINE A.K, JOHNSON M.W. – Peripheral Choroidal Neovascularization. *Eur J Ophthalmol* 1996;6:44-49.

.....

Correspondence and reprints
Nanny COLLAER
Lindestraat 42
B-3210 Linden
nanny_collaer@hotmail.com
België