SERPIGINOUS CHOROIDITIS TREATED IN A STEPLADDER APPROACH

DEPLA J.A., VAN CALSTER J.**

ABSTRACT

We present a case of serpiginous choroiditis in a 46-year-old graphic designer. The development of multiple scotomata urged the use of immunosuppressants although his visual acuity remained 20/20. A successful combination of corticosteroids, azathioprine and methotrexate was used in a stepladder approach. No new retinal lesions developed until the end of follow-up (18 months). Thanks to his profession, the patient enabled us to give an unique representation of his visual symptoms.

SAMENVATTING

We stellen een casus voor van een 46-jarige grafisch ontwerper met serpigineuse choroïditis. Hoewel de visus 20/20 bleef, bleek de ontwikkeling van meerdere scotomen het toedienen van immunosuppressiva noodzakelijk te maken. Een succesvolle combinatie van opeenvolgend corticosteroïden, azathioprine en methotrexaat werd toegediend. Tot het einde van de follow-up ontwikkelden zich geen nieuwe retinale letsels. Dankzij zijn beroep kon hij ons een unieke voorstelling geven van zijn visuele gewaarwordingen.

RÉSUMÉ

Nous présentons un cas de choroïdite serpigineuse chez un homme âgé de 46 ans, graphiste de profession. Tout en gardant une acuité visuelle de 20/20, le développement de multiples scotomes nécessitait l'utilisation d'agents immunodépresseurs. Nous avons utilisé avec succès un traitement composé de corticostéroïdes, azathioprine et méthotrexate. Aucune récidive ne s'est développée pendant la durée du suivi. Sa profession lui permettait de nous donner une représentation précise de ses symptômes visuels.

KEY WORDS

Serpiginous choroiditis; serpiginous choroidopathy; visual symptoms; posterior uveitis

MOTS-CLÉS

Choroïdite serpigineuse; choroïdopathie serpigineuse; symptômes visuels; uvéite postérieure

.....

* *Department of Ophthalmology, UZ Leuven, Leuven, Belgium*

received: 21.06.07
accepted: 29.08.07

INTRODUCTION

We present a case of serpiginous choroiditis in a graphic designer. His profession urged the use of multiple immunosuppressive drugs to stop scotomata from developing, although his visual acuity remained at the 20/20 level ODS. His profession enabled him to make an unique representation of his visual symptoms.

CASE REPORT

A 46-year-old man presented with a 3-day history of blurred vision in his left eye. The fundoscopic and fluorescein angiographic examination were suggestive of serpiginous choroiditis (Fig 1).
A thorough systemic medical workup and anterior chamber tap were negative for the following infectious causes : Toxoplasma Gondii, Treponema Pallidum, Borrelia Burgdorferi, Herpes Simplex virus, Varicella-Zoster virus, Cytomegalovirus and Epstein-Barr virus. Chest X-ray, computed chest tomography and inflammatory parameters were normal. Following corticosteroid therapy (methylprednisolone 64 mg/day), the inflammation quickly resolved and atrophy ensued. The fovea was not involved, hence visual acuity improved to 20/20. During corticosteroid tapering to 4 mg/day, new retinal lesions developed 7 months after initial examination. We added azathioprine 100 mg/day. As it takes time before the effect of azathioprine occurs, we also increased corticosteroid therapy to 16 mg/day.

Nine months after initial examination the patient noticed photopsias, dyschromatopsia and paracentral metamorphopsia in the previously normal right eye. Visual acuity remained 20/20 ODS. Fundoscopic examination revealed new lesions in the right eye (Fig 2).
Concomitant therapy with methotrexate 7,5 mg/week and folic acid 1 mg/day was instituted. Due to his profession as a graphic designer, he was able to make an unique representation of his visual symptoms (Fig 3, Fig 4). Over the course of 8 weeks new lesions and scotomata developed. Methotrexate therapy was increased to 15 mg/week which stabilised his scotomata and visual acuity at the 20/20 level ODS. The patient is currently on methylprednisolone 16 mg/day, azathioprine 100 mg/day, methotrexate 15 mg/week and folic acid 1 mg/day. No new lesions developed until the end of follow-up (18 months).

Extensive scarring was present in the left eye, while in the right eye the process was halted early in the course of the disease (Fig 5, Fig 6).

DISCUSSION

Serpiginous choroiditis has been described as a relentlessly progressive inflammation. Indeed,

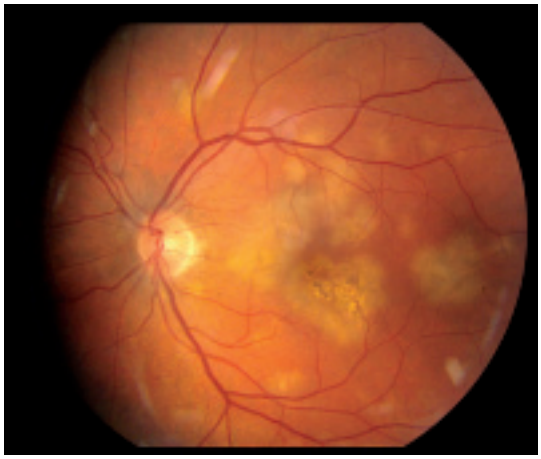

Figure 1: Color fundus photograph of the left eye at presentation, showing early appearance of active yellow creamy lesions.

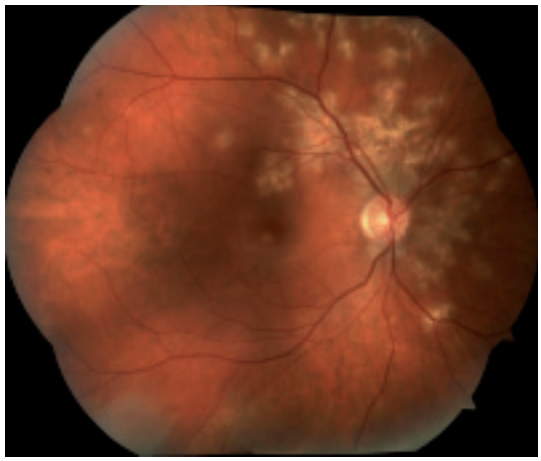

Figure 2: Color fundus photograph of the right eye at presentation of visual symptoms, showing area of active yellow lesions and atrophy.

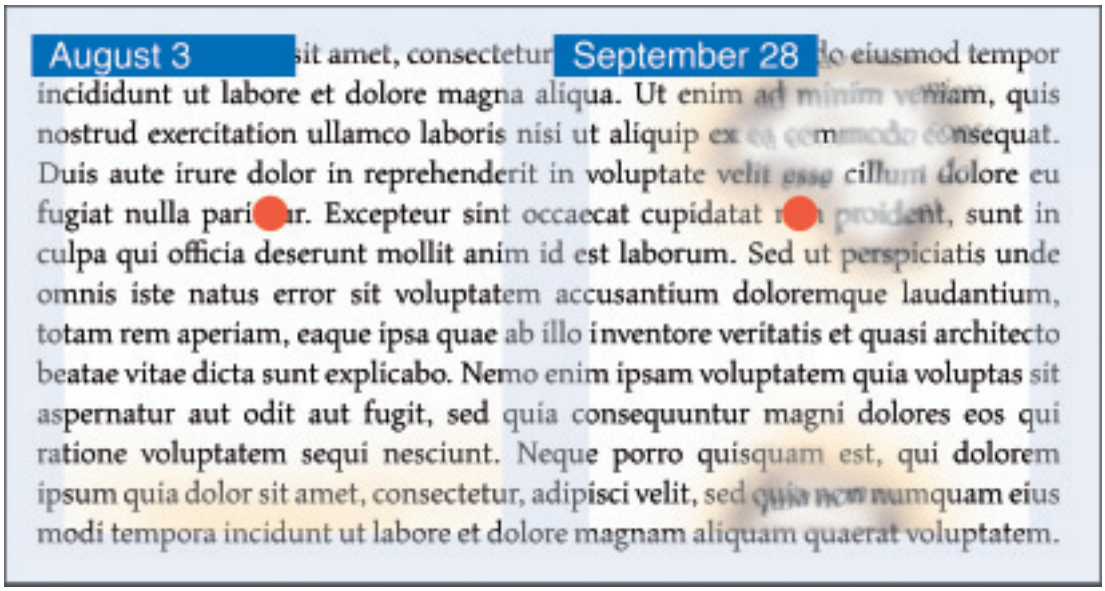

Figure 3: Documentation obtained from the patient, showing initial visual symptoms of the right eye. The lesions in the right eye presented initially as a haze zone inferiorly (left), rapidly enlarging and becoming more dense over 8 weeks (right) (red dot showing fixation point).

the natural course is progressive with multiple relapses leading to potentially significant visual loss (7, 9). Aggressive treatment with immunosuppressants is warranted only to have a modest effect on the rate of recurrence and progression (1,6). One of the problems of affirming treatment efficacity is that disease progression is frequently only noticeable on fluorescein angiography or by means of serial fundoscopic photographs. In this case Amsler testing at home proved a reliable asset to detect newly emerging lesions and could replace serial fundoscopic photographs. Newer objective tests are available nowadays and could be of particular interest in this disease to match the subjective visual symptoms to objective parameters. Progress towards the fovea can be accurately determined using spectral OCT, multifocal ERG and microperimetry. These objective data will aid the clinician in deciding when to alter the treatment.

Serpiginous choroiditis is thought to be an immunologic disease. Histopathologic studies showed diffuse and focal infiltrates of lymphocytes in the choroid, in a greater number at the margin of the lesion than in the center of the lesion (10). This inflammatory component of the disease is the rationale for instituting anti-inflammatory and immunosuppressive therapy. Together with the inflammation, occlusion of the choriocapillaris is a key feature of ser-



Figure 4: Amsler testing of the left eye of the patient, 10 months after initial examination (Documentation obtained from patient)

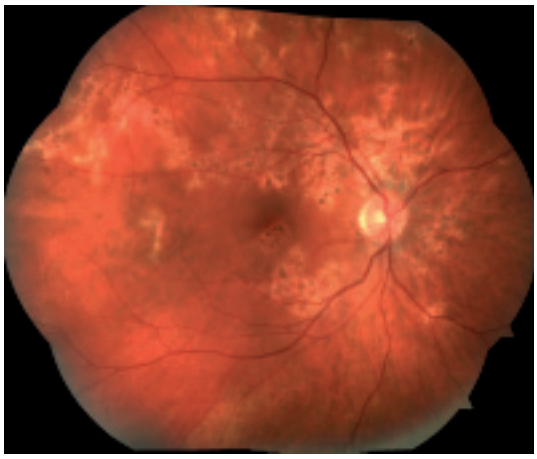

Figure 5: Color fundus photograph of the right eye at the end of follow-up, showing mild scarring due to adjustment of therapy.

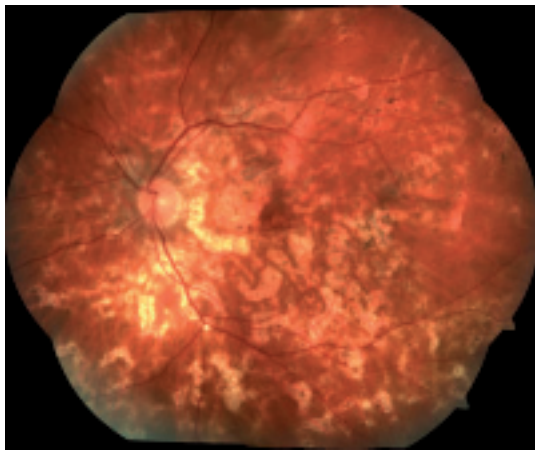

Figure 6: Color fundus photograph of the left eye at the end of follow-up, showing extensive scarring.

piginous choroiditis (4). This occlusion and inflammation of the choroid leads to secondary involvement of the retina and produces the typical geographic atrophy (3).

The goal of therapy is to rapidly control active lesions and to prevent further recurrences. It is difficult as a clinician to institute systemic immunosuppression with its serious side effects while the visual acuity of the patient remains 20/20 and only one eye is involved. Furthermore, the scarcity of data in the literature regarding the optimal treatment of serpiginous choroidopathy, as highlighted by Jabs and associates, makes the decision even more complex (6). Albeit, the paracentral scotomata shown in figure 2 were so largely disabling the patient in his profession as a graphic designer, that we decided to institute immunosuppressants. After a first relapse while tapering corticosteroids, we chose to add azathioprine to the treatment regimen, as suggested by Vianna et al., instead of the triple-agent therapy (cyclosporine A, azathioprine and corticosteroids) (5, 8). In their series of 4 patients, they achieved remission in 3 out of 4 patients with this therapy. The remaining patient experienced a relapse which necessitated the addition of methotrexate, like in our case. This so called 'stepladder approach' has its main advantage in initially using only one immunosuppressant instead of 2. Hence the chance of decreasing serious systemic side effects likewise. It has been suggested that azathioprine is effective for the treatment of chronic uveitis mainly if used in conjunction with corticosteroids (2). For that reason we chose not to lower the corticosteroid therapy below 16 mg/day. From month 11 after initial examination until month 18, this therapy was succesful in preventing recurrence. The main complaints of our patient are gastrointestinal problems, fatigue and recurrent upper airway infections, making the continuation of the immunosuppressants a burden to him. Nevertheless, he is able to cope with these side effects related to the intake of the immunosuppressants considering the favourable clinical outcome. It is a fact that triple-agent therapy is very difficult to maintain for the patient.

CONCLUSION

Our case confirms this stepladder approach to be a valuable alternative to the triple-agent therapy, especially if only one eye is involved initially and the fovea is spared. Giving 2 immunosuppressants simultaneously from the start could jeopardize patient's compliance. In case of worsening in the clinical symptoms while on monotherapy, adding an immunosuppressant will be more tolerable and logical to the patient. Besides, it is known from the literature that the majority of patients will not need a second immunosuppressant anyhow. This stepladder approach will avoid more serious systemic side effects.

REFERENCES

(1) CHRISTMAS N.J., OH K.T., OH D.M., FOLK J.C. – Long-term follow-up of patients with serpinginous choroiditis. Retina 2002; 22: 550-6

(2) FOSTER C.S. – Pharmacologic treatment of immune disorders. In : ALBERT D.M., JAKOBIEK F.A., eds. Principles and Practice of Ophthalmology. Philadelphia, Pa : SAUNDERS W.B. Co; 2000: 346-54

(3) GASS J.D.M. – Inflammatory diseases of the retina and choroid. In : Stereoscopic atlas of macular diseases: diagnosis and treatment. 4th ed. St. Louis: CV Mosby, 1997; 158-165

(4) GIOVANNINI A., MARIOTTI C., RIPA E., SCASSELLATI-SFORZOLINI B. – Indocyanine green angiographic findings in serpiginous choroidopathy. Br J Ophthalmol 1996; 80: 536-40

(5) HOOPER P.L., KAPLAN H.J. – Triple agent immunosuppression in serpiginous choroiditis. Ophthalmology 1991; 98: 944-51

(6) JABS D.A., ROSENBAUM J.T., FOSTER C.S., HOLLAND G.N., JAFFE G.J., LOUIE J.S., NUSSENBLATT R.B., STIEHM E.R., TESSLER H., VAN GELDER R.N., WHITCUP S.M., YOCUM D. – Guidelines for the use of immunosuppressive drugs in patients with ocular inflammatory disorders: recommendations of an expert panel. Am J Ophthalmol 2000; 130: 492-513

(7) LIM W.K., BUGGAGE R.R., NUSSENBLATT R.B. – Serpiginous choroiditis. Surv Ophthalmol 2005; 50: 231-44

(8) VIANNA R.N.G., ÖZDAL P.Ç., DESCHÊNES J., BURNIER M.N. – Combination of azathioprine and corticosteroids in the treatment of serpiginous choroiditis. Can J Ophthalmol 2006; 41: 183-9

(9) WEISS H., ANNESLEY W.H. Jr, SHIELDS J.A., TOMER T., CHRISTOPHERSON K. – The clinical course of serpiginous choroidopathy. Am J Ophthalmol. 1979; 87: 133-142

(10) WU J.S., LEWIS H., FINE S.L., GROVER D.A., GREEN W.R. – Clinicopathologic findings in a patient with serpiginous choroiditis and treated choroidal neavascularization. Retina 1989; 9: 292-301

.....

Address for correspondence and reprints:

J. VAN CALSTER
Dept.of Ophthalmology, UZ Leuven
Kapucijnenvoer 33
B-3000 Leuven
BELGIUM
Phone: +32-16-33 26 60 Fax: +32-16-33 23 67
E-mail: Joachim.Vancalster@uz.kuleuven.ac.be