
ACUTE VISUAL FIELD CONSTRICTION IN OPTIC DISC DRUSEN: REPORT OF AN UNUSUAL CASE

*HENDRIKS W.**, *STALMANS I.**,
*VAN CALSTER J.**, *SNYERS B.***, *ZEYEN T.**

SUMMARY

We describe a case of an acute symptomatic and non-progressive visual field constriction in one eye of a 19-year-old female with optic disc drusen. The fellow eye showed slowly progressive visual field defects. A limited or retrolaminar infarction of the optic nerve head seems a plausible cause of the acute visual field loss. The slow progression in the fellow eye is most probably due to mechanical compression by the drusen. The case is documented with Humphrey perimetry during a follow-up of 11 years and with Color Doppler Imaging (CDI) of the optic nerve.

SAMENVATTING

Wij beschrijven een casus van een 19-jarige vrouw met papildrusen. Zij ondervond een plotse gezichtsvelduitval aan één oog en deze uitval was niet evolutief in de tijd. Het andere oog vertoonde traag progressieve gezichtsvelddefecten. Een beperkt of retrolaminair infarct van de papil lijkt een plausible verklaring te zijn voor de acute gezichtsvelddaling. De trage progressie in het andere oog is waarschijnlijk een gevolg van mechanische compressie door de drusen. De casus werd gedocumenteerd met Humphrey-perimetrie gedurende een follow-up van 11 jaar en met Color Doppler Imaging (CDI) van de papil.

RÉSUMÉ

Nous décrivons le cas d'une femme âgée de 19 ans avec drusen papillaires. Elle présentait une restriction concentrique brutale et non évolutive du champ visuel d'un oeil. L'autre oeil montrait des déficits du champ visuel lentement progressifs. Un infarctus limité ou rétrolaminaire de la papille semble une cause plausible de la perte aiguë du champ visuel. La lente progression dans l'autre oeil est probablement le résultat d'une compression mécanique par les drusen. Le cas est documenté par périmétrie de Humphrey pendant un suivi de 11 ans et avec Color Doppler Imaging (CDI) de la papille.

KEY WORDS

Optic disc drusen - visual field - perimetry - Color Doppler Imaging (CDI) - anterior ischemic optic neuropathy (AION)

MOTS-CLÉS

Drusen papillaires- champ visuel - périmétrie - Color Doppler Imaging (CDI) - neuropathie optique ischémique antérieure (NOIA)

.....

* *Department of Ophthalmology, University Hospital Sint-Rafaël, B-3000 Leuven*

** *Department of Ophthalmology, University Hospital Saint-Luc, B-1200 Brussels*

received: 04.09.07

accepted: 07.11.07

INTRODUCTION

Optic disc drusen are acellular, often calcified nodules within the substance of the optic nerve head. They are thought to result from disturbance of the axonal transport and deposition of debris in eyes with a small scleral canal and a congenitally abnormal disc vasculature, allowing transudation of plasma proteins (6,12,17,20). On funduscopy, the optic discs show a "lumpy bumpy border" and have bright irregular deposits. In children however, superficial and visible drusen are very rare. These buried optic disc drusen produce elevation of the optic disc and hazy disc margins, mimicking papilledema. Another important differential diagnosis is glaucoma, as slowly progressive, asymptomatic visual field defects occur commonly in optic disc drusen while cupping is not present. Furthermore, patients with a small scleral canal and optic disc drusen are predisposed to vascular complications because of mechanical compression of the disc vessels. Although rare, these complications are responsible for an often dramatic, sudden visual impairment.

CASE REPORT

A 19-year-old white American female first consulted our department in 1995 with complaints of acute visual field loss in the left eye, noticed one day earlier upon awakening. She was treat-

ed with acetylsalicylic acid and dipyridamole because of a history of venous thrombosis in the leg. In 1988 she was diagnosed with optic disc drusen in the United States.

Visual acuity was 10/10 in both eyes. Clinical examination revealed a relative afferent pupillary defect in the left eye. Red saturation and light sensitivity were diminished in the left eye. Ishihara color testing and anterior segment examination were normal. Intraocular pressure was 18 mmHg in both eyes. Fundus examination showed bilateral optic disc drusen but no evidence of disc edema (fig. 1). Ultrasonography showed calcification within the disc drusen. Autofluorescence was documented (fig. 2). Fluorescein angiography (fig. 3) and a cerebral MRI were normal. Goldmann perimetry showed constriction of the visual field and scotomas in the left eye. Humphrey perimetry revealed a ring scotoma in the left eye and arcuate defects in the right eye (fig. 4,5). She was treated with timolol in both eyes to avoid further deterioration of her visual fields. One week later, pallor of the left optic disc was noted.

In the following 11 years, visual symptoms remained the same. The intraocular pressure remained within normal limits (14-18 mmHg) despite limited compliance to the IOP-lowering medication. Successive Humphrey perimetries showed a stable visual field of the left eye while the arcuate defects of the right eye seemed to be slowly progressive (fig.4,5).

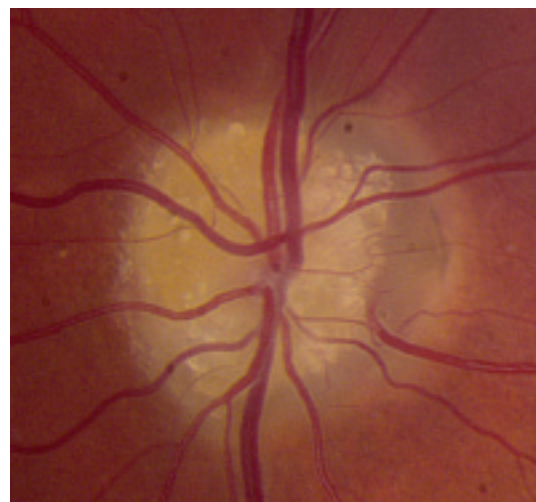
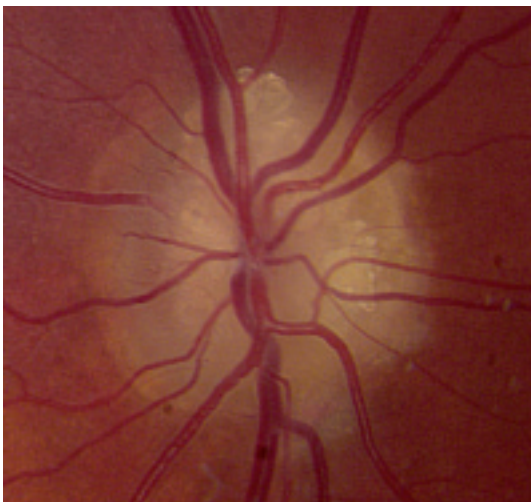

Figure 1: Obvious optic disc drusen in the right and left optic disc.

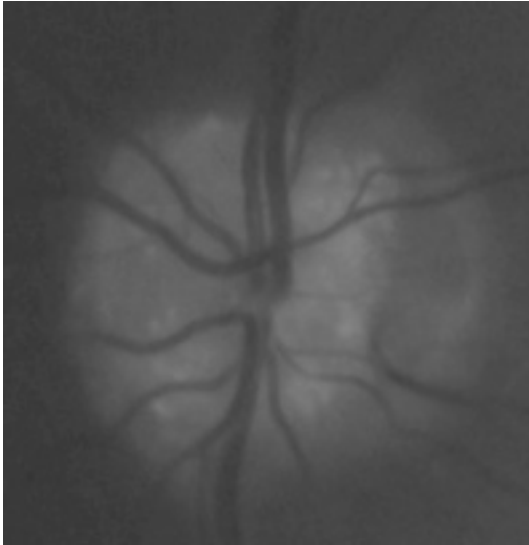


Figure 2: Autofluorescence of the left optic disc

HRT documented a thinned retinal nerve fibre layer. A cerebral MRI made in 2006 was still completely normal. Recently we performed Color Doppler Imaging (CDI) of the vascular supply of the optic nerves. We found attenuated flow velocities of the small retrobulbar vessels of both eyes. A normal flow was found in the ophthalmic arteries (fig. 6).

DISCUSSION

Once the diagnosis of optic disc drusen is established, the condition is usually considered to have a good visual prognosis. In fact, most patients with optic disc drusen are asymptomatic. Transient visual obscurations or episodic visual loss can occur, as described by Lorentzen in 8,6% of his patients (10). Visual acuity is only infrequently decreased in cases of optic disc drusen (10,13,19). Severe loss is rare and is mostly associated with severe visual field defects (2,8,18).

Visual field defects develop in 24-87% of adult eyes with optic disc drusen and are more frequent and most prominent in eyes with superficial drusen. The following patterns have been described: arcuate scotomas - especially in the inferior nasal quadrant -, enlargement of the blind spot and/or concentric narrowing. However, drusen seem to be responsible only for the

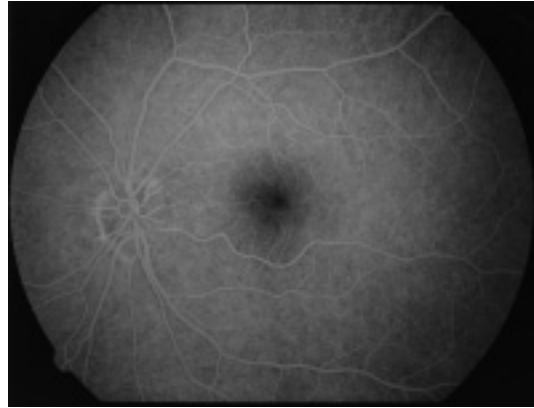


Figure 3: Fluorescein angiography showing a normal optic disc.

peripheral loss while blind spot enlargement is probably due to concomitant papilledema in cases with leaking optic disc vessels (1). To our knowledge, there are no studies on progression of visual field defects documented by automated perimetry, but this is well investigated by Goldmann and/or Friedmann perimetry (9, 14). This slow visual field deterioration can be explained by impaired axonal transport and gradual attrition of optic nerve fibres due to compression in an eye with a small scleral canal (21,22), or by direct compression of the nerve fibres by drusen (9,10).

On the other hand, a more rapid decline of vision can occur, with or without a concomitant impairment of visual acuity. Loss of visual acuity, especially if pronounced, progressive or not accompanied by visual field loss, should lead to a careful search for a concomitant lesion, particularly an intracranial mass (2,16). However, most cases of acute visual loss can be attributed to vascular complications as a result of compression by the small scleral canal and by the drusen themselves. A number of cases of central retinal artery and central retinal vein occlusion associated with drusen have been reported (1,4) and anterior ischemic optic neuropathy (AION) is the most common cause of visual loss in optic disc drusen. In contrast with the classic form of AION, patients are young adults and most of them have no cardiovascular disease (1). We found sporadic reports of optic disc drusen with acute visual loss and without apparent disc changes or vascular dis-

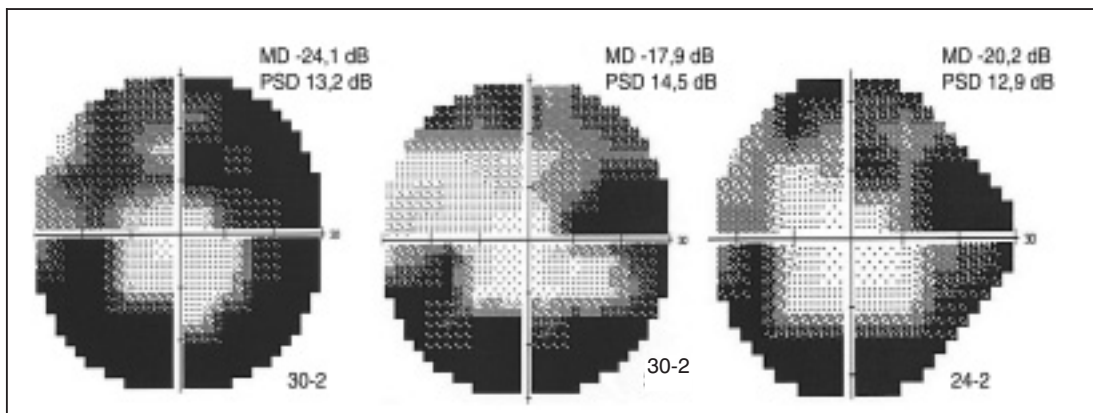


Figure 4: Humphrey visual field evolution in the left eye (1995, 1997, 2006): stable ring scotoma.

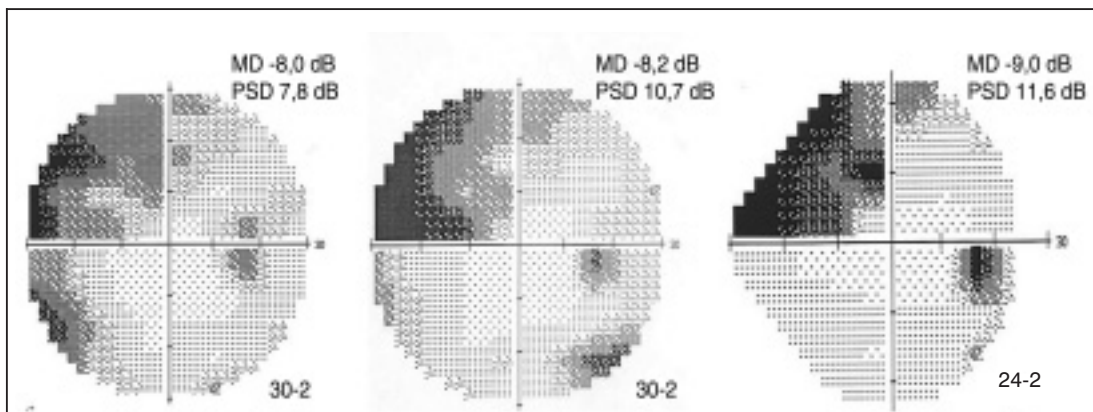


Figure 5: Humphrey visual field evolution in the right eye (1995, 2005, 2006): progressive arcuate defects.

turbance. Beck et al. suggested ischemia of the optic nerve to explain the acute and episodic nature of visual loss in several eyes in their series. Only one patient was found to have disc edema, although most of their patients were not examined in the acute phase (2). The same mechanism could also explain the fast evolution of visual loss in a patient reported by Fanti et al. (3), in a patient reported by Kamin et al. (7) and in the 2 patients reported by Moody et al. (11).

In our case, there was no disc edema but the disc became pale. A possible explanation is a limited infarction of the optic nerve head or an infarction in the retrolaminar portion of the optic nerve head (15). As with nonarteritic AION, this would involve a decrease in perfusion pres-

sure within the optic nerve head that, in susceptible individuals, leads to infarction (5). The susceptibility in optic disc drusen may be related to crowding of the optic nerve head, as well as to the often associated various vascular anomalies (1). In this regard, the diminished flow velocities in our patient, as shown by color Doppler imaging, provide a clear illustration. In addition, other cardiovascular risk factors could have played a role. Our patient discovered her visual loss upon awakening, which could mean an influence of nocturnal hypotension. The history of venous thrombosis in the leg of our patient is also noteworthy.

In conclusion, we report a case of sudden constriction of the visual field in the context of optic disc drusen without disc edema or retinal

vascular complications. The history and the pale optic disc are suggestive of ischemia of the optic nerve head. Possibly color Doppler imaging of the optic nerve may be a useful tool in determining the risk profile for ocular vascular accidents in patients with optic disc drusen. More concretely, CDI could be of value in considering long-term antithrombotic therapy in patients with optic disc drusen.

REFERENCES

- (1) AUW-HAEDRICH C., STAUBACH F., WITSCHEL H. – Optic disk drusen. *Surv Ophthalmol.* 2002; 47:515-532
- (2) BECK R.W., CORBETT J.J., THOMPSON H.S., SERGOTT R.C. – Decreased visual acuity from optic disc drusen. *Arch Ophthalmol.* 1985; 103:1155-9

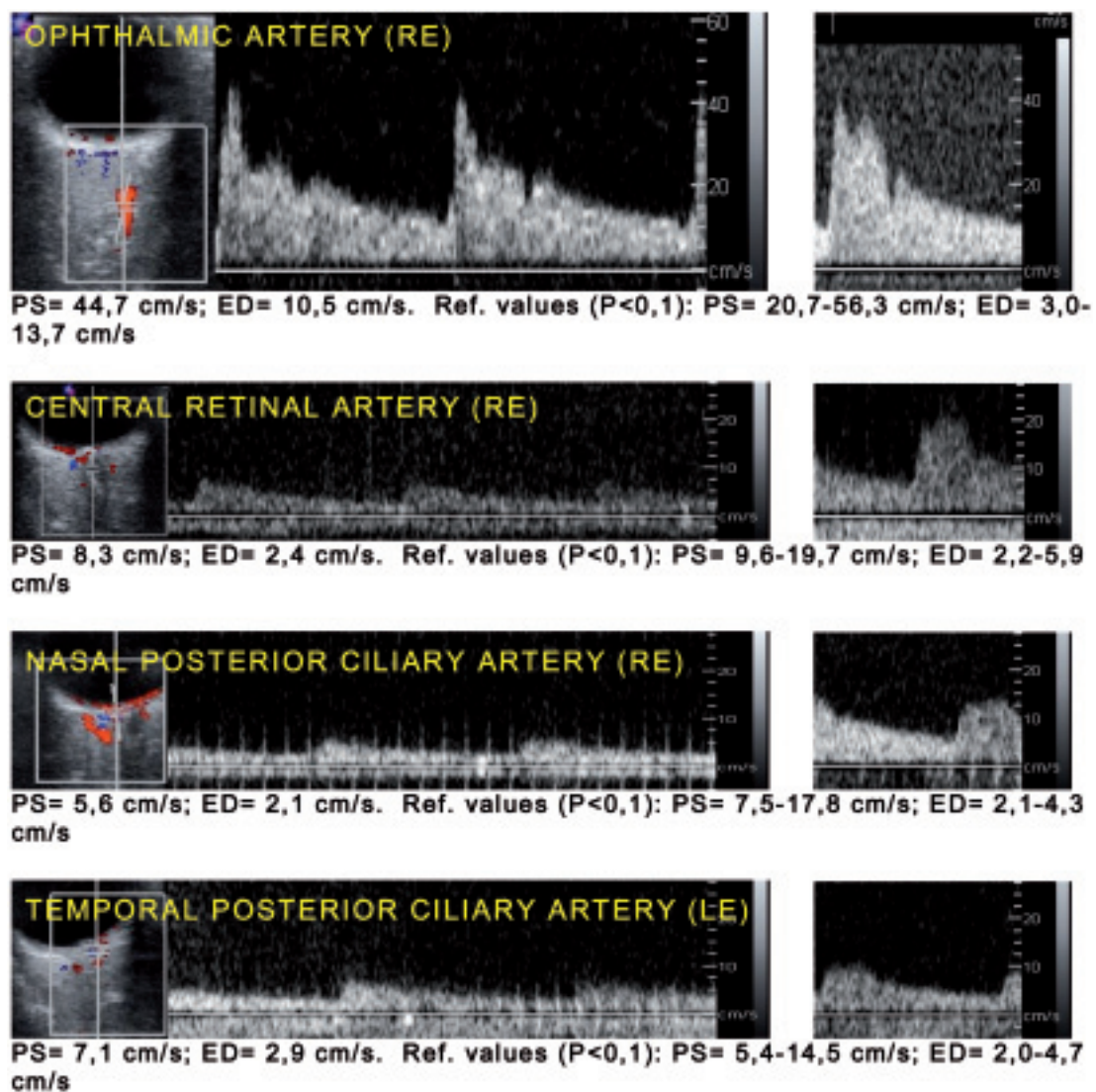


Figure 6: Left - Color Doppler Imaging of our patient: note the values of the peak systolic (PS) and end diastolic (ED) flow in the small retrobulbar vessels at the lower limit and the normal flow in the ophthalmic artery. Right - Color Doppler Imaging of a normal patient, for comparison.

- (3) FANTI A., GATTI M., TOSTI G., LAZZARONI F. – Central vision impairment from optic disk drusen in the young. *Metab Pediatr Syst Ophthalmol.* 1990; 13:85-7
- (4) FARAH S.G., MANSOUR A.M. – Central retinal artery occlusion and optic disc drusen. *Eye* 1998; 12:480-482
- (5) HAYREH S.S. – Acute ischemic disorders of the optic nerve: pathogenesis, clinical manifestations and management. *Ophthalmol Clin North Am* 1996; 9:407-442
- (6) JONAS J.B., GUSEK G.C., GUGGENMOOS-HOLZMAN I., NAUMANN G.O. – Optic nerve head drusen associated with abnormally small optic discs. *Int. Ophthalmol* 1987; 11:79-82
- (7) KAMIN D.F., HEPLER R.S. – Optic Nerve Drusen. *Arch Ophthalmol.* 1973; 89:359-362
- (8) KNIGHT I., HOYT W.F. – Monocular blindness from drusen of the optic disk. *Am. J Ophthalmol* 1972; 73:890-2
- (9) LANSCHKE R.K., RUCKER C.W. – Progression of defects in visual fields produced by hyaline bodies in optic disks. *AMA Arch Ophthalmol.* 1957; 58:115-21
- (10) LORENTZEN S.E. – Drusen of the optic disk. A clinical and genetic study. *Acta Ophthalmol (Copenh).* 1966; Suppl 90:1-180
- (11) MOODY T.A., IRVINE A.R., CAHN P.H., SUSAC J.O., HORTON J.C. – Sudden visual field constriction associated with optic disc drusen. *J Clin Neuroophthalmol.* 1993; 13:8-13; discussion
- (12) MULLIE M.A., SANDERS M.D. – Scleral canal size and optic nerve head drusen. *Am J Ophthalmol.* 1985; 15:99:356-9
- (13) MUSTONEN E. – Pseudopapilloedema with and without verified optic disc drusen. A clinical analysis I. *Acta Ophthalmol.(Copenh)* 1983; 61:1037-56
- (14) MUSTONEN E. – Pseudopapilloedema with and without verified optic disc drusen. A clinical analysis II: visual fields. *Acta Ophthalmol. (Copenh)* 1983; 61:1057-66
- (15) PURVIN V., KING R., KAWASAKI A., YEE R. – Anterior ischemic optic neuropathy in eyes with optic disc drusen. *Arch Ophthalmol.* 2004; 122:48-53
- (16) RUCKER C.W., KEARNS I.P. – Mistaken diagnosis in some cases of meningioma. *Clinics in perimetry No. 5. Am. J. Ophthalm.* 1961; 51:15-19
- (17) SACKS J.G., O'GRADY R.B., CHOROMOKOS E., LEESTMA J. – The pathogenesis of optic nerve drusen. A hypothesis. *Arch Ophthalmol* 1977; 95:425-8
- (18) SANDERS T.E., GAY A.J., NEWMAN M. – Drusen of the optic disk-hemorrhagic complications. *Trans Am Ophthalmol Soc.* 1970 ; 68:186-218
- (19) SCHOLL G.B., SONG H.S., WINKLER D.E., WRAY S.H. – The pattern visual evoked potential and pattern electroretinogram in drusen-associated optic neuropathy. *Arch. Ophthalmol* 1992; 110:75-81
- (20) SEITZ R., KERSTING G. – Die Drusen der Sehnervenpapille und des Pigmentepithels. *Klin. Monatsbl Augenheilkd* 1962; 152:75-82
- (21) SPENCER W.H. – XXXIV Edward Jackson Memorial Lecture: drusen of the optic disc and aberrant axoplasmic transport. *Ophthalmology* 1978; 85:21-38
- (22) TSO M.O. – Pathology and pathogenesis of drusen of the optic nerve head. *Ophthalmology* 1981; 88:1066-80
-
- Correspondence and reprints:*
- Prof. Dr. T. ZEYEN*
Dept. of Ophthalmology UZ Leuven
Kapucijnenvoer 33
B-3000 LEUVEN, Belgium
E-mail: thierry.zeyen@uz.kuleuven.ac.be