

# THE SIGNIFICANCE OF SOME OBSERVATIONS ON AFRICAN OCULAR ONCHOCERCIASIS DESCRIBED BY JEAN HISSETTE (1888-1965)

KLUXEN G. \*, HOERAUF A. \*\*

## SUMMARY

One of the most significant contributions to tropical medicine and ophthalmology was made by Jean Hissette: African ocular onchocerciasis (4,6). During his extensive investigations in the Babindi country, he found numerous adults with river blindness. Their eye disease was caused by the filaria *Onchocerca volvulus* Leuckart. He noticed the signs of interstitial keratitis and band keratopathy, faint iritis or iridocyclitis, posterior synechiae and often a downward distortion of the pupil. He was the first to describe chorioretinal scarring of the fundus, what became known as the Hissette-Ridley fundus. People reported to him their entoptic phenomena which he unequivocally interpreted to be the images of microfilariae in the patient's own eye. During his stay in Belgium in 1932, he elucidated the pathogenesis of blindness since he was able to provide histological proof of the presence of microfilariae in various ocular tissues of an enucleated eye from a patient living near the Sankuru river. Like other serious health impairments, the severe inflammatory lesions in the eye occurred only after the microfilariae had died. Hence he realized that dying microfilariae play a key role in the mechanisms leading to blindness. Hissette's precise descriptions were the logical fruit of his outstanding observational abilities and

enabled him as a man of great intuition to speculate about causal relationships. He evidently benefited from the fact that he took the native Africans seriously and asked them their opinion. In 1933, his friend and teacher Dr. De Mets in Antwerp already wrote on Hissette's discovery in the Belgian Congo: "This study is of exceptional value to specialists which is not only a tribute to its author, but to our common native country (Belgium)." (5).

## RÉSUMÉ

La médecine tropicale et l'ophtalmologie doivent au docteur Jean Hissette l'une de leurs plus importantes découvertes: l'onchocercose oculaire africaine (4,6). Dans une longue enquête au pays des Babindi, Hissette trouva de nombreux cas d'adultes devenus aveugles à cause de la "cécité des rivières". C'étaient les filaires *Onchocerca volvulus* Leuckart qui provoquaient cette nouvelle affection oculaire. Il observa chez les malades des signes de kératite interstitielle, de kératopathie en bandelette, d'iritis torpide ou d'irido-cyclite, des synéchies postérieures et souvent une correctopie vers le bas. Il fut le premier à décrire les cicatrices choriorétiniennes à l'examen ophtalmoscopique, correspondant à ce que l'on dénomme aujourd'hui le fond d'œil de Hissette-Ridley. Les malades se plaignaient fréquemment de voir des corps étrangers intraoculaires. Hissette a attribué ces phénomènes entoptiques à la présence de microfilaries dans les milieux de l'œil. Pendant son séjour en Belgique en 1932, Jean Hissette fit la démonstration histologique du mécanisme pathologique de la cécité quand il trouva des microfilaries dans différents tissus d'un œil énucléé qu'il avait rapporté de la région du Sankuru. Parmi d'autres effets préjudiciables à la santé, ces microfilaries mortes jouent un rôle principal dans les réactions inflammatoires graves qu'elles induisent. Hissette fut le premier à réaliser que la mort des microfilaries entraînait la cécité chez les patients atteint d'onchocercose. Ses qualités particulières d'observateur lui ont permis d'en donner des descriptions scientifiques très pré-

.....

\* *Augenärztliche Gemeinschaftspraxis  
Brückenweg 1  
D-42929 Wermelskirchen  
Germany*

\*\* *Institute of Medical Microbiology, Immunology and  
Parasitology  
University Clinic Bonn  
Sigmund Freud Str. 25  
D-53105 Bonn  
Germany*

Submitted: 14.12.07

Accepted: 13.02.08

cises et son intuition instinctive d'en comprendre les mécanismes pathogéniques. Sa compréhension de la maladie fut aussi facilitée par le fait qu'il écoutait attentivement les Africains et qu'il tenait compte de leur avis. Son ami et professeur, le docteur De Mets d'Anvers, écrivit en 1933: «Pour notre spécialité, ce travail a une valeur tout à fait exceptionnelle qui fait honneur à son auteur et à notre commune patrie (la Belgique)» (5).

## ZUSAMMENFASSUNG

Die Tropenmedizin und die Ophthalmologie verdanken Jean Hissette eine ihrer bedeutenden Entdeckungen: die afrikanische okuläre Onchocerkose (4,6). Bei seinen umfangreichen Untersuchungen im Lande der Babindi fand er zahlreiche erwachsene Flussblinde. Verursacht war deren Augenerkrankung durch die Filarie *Onchocerca volvulus* Leuckart. Er sah die Zeichen der interstitiellen Keratitis und der bandförmigen Hornhautdegeneration, der leichten Iritis oder Iridozyklitis, hintere Synechien und häufig eine Verziehung der Pupille nach unten. Er beschrieb als erster den chorioretinitischen Narbenfundus, der heute Hissette-Ridley-Fundus genannt wird. Die Leute berichteten ihm von entoptischen intraokularen Wahrnehmungen, die er ohne jeden Zweifel für die Wahrnehmungen von Mikrofilarien im eigenen Auge erkannte. Während seines Aufenthaltes in Belgien 1932 klärte er die Pathogenese der Erblindungen auf, als er Mikrofilarien in verschiedenen Augengeweben eines enukleierten Auges vom Sankuru histologisch nachweisen konnte. Neben anderen nachteiligen gesundheitlichen Beeinträchtigungen, entstanden die schweren Entzündungen in den Augen erst, nachdem die Mikrofilarien abgestorben waren. Diesen Umstand erkannte er als den hauptsächlichen Grund, der zu den Erblindungen führte. Die Präzision seiner Beschreibungen verdankte Hissette seiner besonderen Beobachtungsgabe und einer Intuition, kausale Zusammenhänge und Ursachen zu errahnen. Dabei ist ihm offensichtlich der Umstand zugute gekommen, dass er die Farbigen ernst nahm und sie nach ihrer Meinung befragte. Schon 1933 schrieb sein Freund und Lehrer Dr. De Mets, Antwerpen, in der scheidetistischen Missionszeitschrift über Hissette's Entdeckung im Kongo: "Für die Fachwelt hat diese Arbeit einen außergewöhnlichen

Wert, was nicht nur seinem Autor sondern unserem gemeinsamen Vaterland (Belgien) zur Ehre gereicht" (5).

## KEY WORDS

River blindness - entoptic perceptions - distortion of the pupil - Hissette-Ridley fundus - onchocerciasis

## MOTS-CLÉS

Cécité de rivière - phénomènes entoptiques - déviation de la pupille - fond d'œil de Hissette-Ridley - onchocercose

## INTRODUCTION

*Onchocerca volvulus* microfilariae released from female worms in subcutaneous nodules, migrate through the skin and can invade the anterior and the posterior segment of the eye. Jean Hissette was the very first to study the pathogenesis of this disease in detail (7, 9, 10, 11). In the anterior segment, microfilariae infiltrate the cornea, where they die as a result of antifilarial therapy or by natural attrition. The dead microfilariae disintegrate and presumably release toxic substances into the immediate environment, substances which were unknown to Hissette. Posterior segment disease manifests as uveitis and chorioretinitis (7). The host inflammatory response results in cellular infiltration, loss of corneal clarity, chorioretinal scarring and optic atrophy. Repeated infiltration in chronically infected individuals eventually leads to complete blindness.

## ONCHOCERCIASIS IN AFRICA AND CENTRAL AMERICA BEFORE 1930

The first persons to mention ocular onchocerciasis were Rodolfo Robles and Rafael Pacheco Luna in Guatemala in 1915/1916 (15, 17). Ophthalmic symptoms and signs were marked in a trias, also known as "Morbus Robles":

1. Filarial worm infection of an adult *Onchocerca* in America,
2. Erisipela de la costa, or red skin inflammation of the coast, a skin disease located on the face,
3. Conjunctivitis and iritis of the anterior segment of the eye. The early investigators (from 1874-1930) of onchocerciasis in Africa made no mention at all of concomitant severe eye disease. Publications of the observations in Central America by Rodolfo Robles and Émile Brumpt in 1917/1919 prompted some specialists in tropical medicine to look for eye disease associated with African onchocerciasis, but they did not describe any eye involvement leading to blindness (2, 18). Ouzilleau and his colleagues however recorded in 1921 one case of keratitis in 16 infected persons in a village near Brazzaville with 27 inhabitants (14).

## IMPORTANT OBSERVATIONS BY JEAN HISSETTE (1888-1965)

### 1. MICROFILARIAE IN THE ANTERIOR CHAMBER

The reports of entoptic observations from African natives suffering from ocular onchocerciasis led Jean Hissette to formulate a specific hypothesis. Hissette observed for the first time people suffering from river blindness in Africa near the Sankuru river in the Belgian Congo in 1930 (7,8). Some villagers with onchocerciasis reported that they occasionally saw against the sky a tangle of black threads or snakes or indeed worms. These observations led Hissette to realise that these must be microfilariae that were able to move freely in the eye (7, 8). During his first stay in the Belgian Congo from 1929 to 1932, Hissette did not have access to a slit lamp (Fig. 1, Fig. 2). Torroella observed freely moving microfilariae of *Onchocerca volvulus* in the aqueous humour of the anterior chamber for the first time in Mexico in 1931 (21).

### 2. THE CHARACTERISTIC DISTORTED PEAR-SHAPED PUPIL

The living worms seem quite harmless, swimming vigorously in the aqueous of the anterior chamber. When dead, however, they fall to the bottom of the anterior chamber forming a grey-brown mass and are associated with a faint iri-

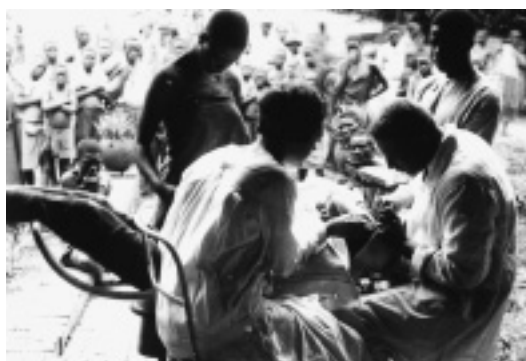

Fig. 1: Jean Hissette and the nurse Mlle de Salmon assisting him with cataract surgery outdoors at Thielen St. Jacques/Kasai, the Belgian Congo 1930.



Fig. 2: Bush doctor Jean Hissette performing a cataract operation in Kasai, the Belgian Congo 1930.

tis. This iritis is relatively mild and not per se a cause of blindness.

Small particles of iris pigment are found on the corneal endothelium, and these also account for the brown colour of the mass in the lower part of the anterior chamber. The resulting inflammatory reaction leads to downward and forward traction of the iris causing an inverted pear-shaped pupil (Fig. 3), one of the characteristic signs of the disease (10,11). The appearance of a downward distorted pupil with an iris attached to a mass in contact with the cornea at first sight mimics the aspect of a perforating corneal ulcer. In spite of the gross distortion of the iris, the slit-lamp reveals a remarkable absence of inflammation except perhaps in the immediate vicinity of the mass. Moreover, there are no signs of ciliary injection, a common finding in case of incarceration

of the iris in a wound. There may well be some atrophy of the iris muscle because the pupils seldom dilate well, even after the instillation of several doses of atropine. This pupil shape may also resemble a coloboma, especially if it is displaced downward and a little toward the nasal side.

The light brown mass at the bottom of the anterior chamber is composed of dead microfilariae, fibrin and chronic inflammatory cells. Occlusion of the filtration angle by mechanical and inflammatory obstruction gives rise to ocular hypertension and glaucoma. This characteristic distorted pear-shaped pupil was also present in 9 out of the 51 Funsu cases (16).

### 3. THE "FLECKED RETINA" OR SCARRED CHORIORETINAL FUNDUS (HISSETTE-RIDLEY)

In 1932, Jean Hissette described the chorioretinal scarring of the fundus in onchocerciasis (7). A first drawing of chorioretinitis resulting from onchocerciasis in Sudan blindness was published in 1935 by J. Bryant (3), a specialist in tropical diseases. It was his correspondence with Hissette that alerted Bryant to the possibility of ocular onchocerciasis. In 1936, Hissette presented a water-color of his own at a colonial exhibition in Brussels (Fig. 4) (10). Despite the fact that Ridley's water-colour followed only nine years later in 1945 (16), the atrophic retina in onchocerciasis was referred

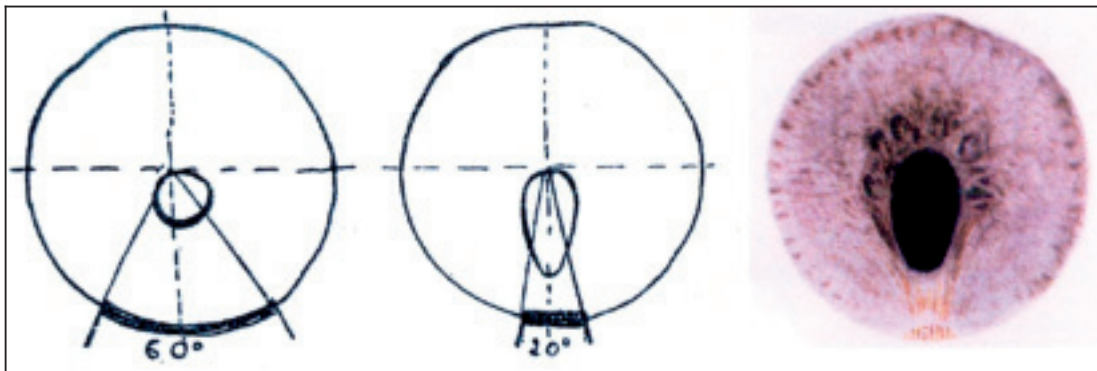


Fig. 3: This pupil in ocular onchocerciasis is displaced downward and its shape is oval with the longer axis vertical, and pear-formed. Dead microfilariae, fibrin and detritus form a sediment in the iridocorneal angle, and the mass then shrinks from 60° to 20° (3 original figures by Jean Hissette).

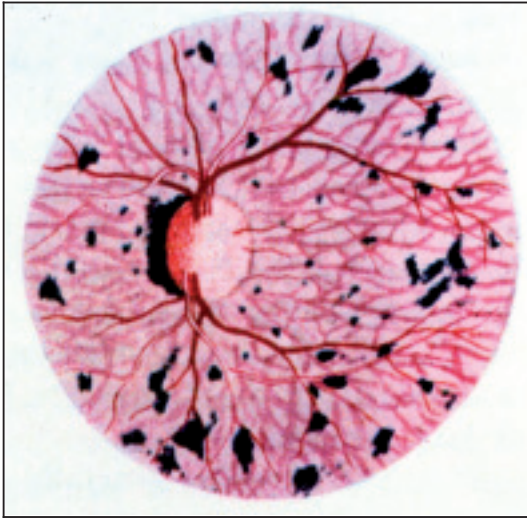

Fig. 4: Scarred fundus with optic atrophy of Louis Kasende 1935, water-colour by Jean Hissette.

to simply as “Ridley fundus”. Now it is more appropriately called “Hissette-Ridley fundus”. Hissette had made a watercolour of the ocular fundus of his patient Louis Kasende in 1935. He came to know Kasende during his first expedition to the Sankuru river in 1931, but had only detected faint iritis and an incipient degeneration of the cornea at that time (7, 8). He had seen this patient back during the Harvard African Expedition of 1934 and saw him again a year later (13). Kasende’s vision had continued to deteriorate and in 1935 he was already severely handicapped (10,11).

#### 4. INFLAMMATORY RESPONSE AFTER DEATH OF THE MICROFILARIAE

Hissette injected living microfilariae in the cornea of an individual with complete atrophy of both optic nerves. He took about fifty microfilariae from the skin of an individual suffering from onchocerciasis and injected them with a fine needle approximately three millimeters from the limbus into clear cornea. Most of the microfilariae flowed back through the opening made by the injection, but two remained inside and could be observed under the microscope. By the third day, they had reached the limit of the limbus, disappeared and reappeared to disap-

pear permanently under the limbus thereafter. Along the course followed by the microfilariae in the cornea, it was not possible to detect the slightest trace of irritation with the slitlamp. However, when Hissette injected dead material of *Onchocerca volvulus* subconjunctivally at the limbus, the neighbouring cornea became opaque for some days. The conclusion seemed obvious: living microfilariae elicited no or only a very slight reaction, whereas dead ones provoked a strong inflammation. According to the “Zeitgeist”, Hissette thought that the latter reaction was probably due to the brisk release of toxins from the disintegrated parasites (10, 11).

## DISCUSSION

In 1930/1931, Jean Hissette reported for the first time that 50% of patients with onchocerciasis suffered from eye problems and that 20% of them were blinded by the disease. He made these seminal observations in an endemic onchocerciasis area near the Sankuru river in the Belgian Congo. Two years later, he found a second focus with the same pathology on the Uélé river. Hissette described the pathogenesis of this form of blindness in a long paper in 1932 (7). In addition to a fine description of anterior eye involvement, he drew attention to the important association with chorioretinitis. The international scientific community reacted to his findings with scepticism and two years later, an American team, the Harvard African Expedition, was sent to the Belgian Congo to verify Hissette’s findings. Richard Pearson Strong and five other Americans traveled to the Sankuru river, financed by the Belgian government. Confronted with this situation, Hissette decided to join them as the seventh member of the expedition. The best school is the field, said Hissette (“la meilleure école est le terrain”) and he showed “his” river blindness patients to the Americans, who finally filmed the same people who had been discovered for the first time in 1930 (12, 13). They confirmed all Hissette’s observations on river blindness caused by onchocerciasis and duplicated his findings in the *American Journal of Tropical Medicine* 1938 (1, 11, 19, 20).

Hissette’s findings were a source of inspiration to investigate the ocular complications of on-



chocerciasis, now known as “river blindness”s, in other parts of Africa (4, 6). In 1944, Harold Ridley found that slightly more than one third of patients with onchocerciasis in a region of the Gold Coast (Ghana) had evidence of either anterior or posterior disease of the eye, with nearly half of them being blind or nearly blind. Ridley’s monograph *Ocular onchocerciasis* was of considerable success in river blindness research (16).

It is ironical that Harold Ridley enjoyed early in his career the success and recognition for the description of ocular onchocerciasis that should have gone to Jean Hissette, whereas recognition for his own original and great contribution to ophthalmology, the introduction of the intraocular lens, was withheld until the end of his very long life.

#### REFERENCES

- (1) BEQUAERT J. – The black-flies, or simuliidae, of the Belgian Congo (Part IV Suppl). *Am J Trop Med Suppl* 1938, 18:116-136.
- (2) BRUMPT E. – Une nouvelle filaire pathogène parasite de l’homme (*Onchocerca caecutiens*, *n.sp.*). *Bull Soc Path Exot* 1919; 12: 464-473.
- (3) BRYANT J. – Endemic retino-chorioiditis in the Anglo-Egyptian Sudan and its possible relationship to *Onchocerca volvulus*. *Trans R Soc Trop Med Hyg* 1935; 28:523-532.
- (4) DE LAEY A. – In memoriam Jean Hissette 1888-1965. *Ann Soc Belge Méd Trop* 1965; 45: 605-606
- (5) DE METS D. – L’onchocercose oculaire au Congo belge. *Bull de l’Aide Médicale aux Missions* 1933; 5: 82.
- (6) HENRY M.C., MAERTENS K., JANSSENS P.G. – Jean Hissette: Profil d’un ophtalmologue tropical. La voie de la découverte de l’onchocercose oculaire africaine. *Bull Séanc Acad Roy Sci Outre-Mer* 1992; 37: 633-644.
- (7) HISSETTE J. – Mémoire sur l’*Onchocerca volvulus* “Leuckart” et ses manifestations oculaires au Congo belge. *Ann Soc Belge Méd Trop* 1932; 12:433-529.
- (8) HISSETTE J. – L’onchocercose oculaire au Congo Belge. Voyage de prospection chez les Babindi, septembre 1930 (à suivre). *Bulletin de l’Aide Médicale aux Missions* 1932; 4:72-75. 1933; 5:14-17. 1933; 5:42-45.
- (9) HISSETTE J. Analogies cliniques entre les onchocercoses américaine et africaine. *Bull Méd Katanga* 1933; 19: 71-83.
- (10) HISSETTE J. – Onchocercose oculaire. *Mém Inst Roy Colon Belge, Sect Sci Nat Méd Suppl* 1937; 5: 1-120.
- (11) HISSETTE J. – Ocular onchocerciasis (Part II Suppl). *Am J Trop Med Suppl* 1938; 18: 58-90.
- (12) JANSSENS PG. – Lutte contre l’onchocercose et soins de santé primaires, Association improductive ou impérieuse. In: *Ophthalmologie tropicale, Onchocercose* (eds. COULAUD JP, GAXOTTE P). Symposium Merck, Sharp & Dohme, Chibret [Dépôt légal] 1982: 151-161
- (13) KLUXEN G. – Harvard African Expedition of 1934 / Dr.Jean Hissette (*DVD Video-Film and book*). *Ophthalmologia Belgica* Brussels 2004.
- (14) OUZILLEAU F., LAIGRET, LEFROU – Contribution à l’étude de l’*Onchocerca volvulus*. *Bull Soc Path Exot* 1921; 14: 717-728.
- (15) PACHECO LUNA R. – Disturbances of vision in patients harbouring certain filarial tumors. *Am J Ophthalmol* 1918; 1: 122-125.
- (16) RIDLEY NHL. – Ocular Onchocerciasis, including an investigation in the Gold Coast. *Brit J Ophthalmol Suppl* 1945; 10: 1-58.
- (17) ROBLES R. Enfermedad nueva en Guatemala. *La Juventud Médica* 1917; 17: 97-115.
- (18) ROBLES R. – Onchocercose humaine au Guatemala produisant la cécité et ‘l’érupción du littoral’ (Erisipela de la costa). *Bull Soc Path Exot* 1919; 12: 442 463.
- (19) SANDGROUND J.H. – Helminthological observations and their bearing on certain aspects of the biology of *onchocerca* (Part III Suppl). *Am J Trop Med Suppl* 1938; 18: 91-115.
- (20) STRONG RP. Onchocerciasis in Africa and Central America (Part I Suppl). *Am J Trop Med Suppl* 1938; 18:1-57.
- (21) TORROELLA JL. Nota sobre la observación de microfilarias de *Onchocerca* in vivo en el ojo humano. *An Soc Méx Oft Otorrin* 1931; 9: 87-88.

.....

*Correspondance and reprint requests:*  
 Prof. Dr. G. Kluxen  
 Augenärztliche Gemeinschaftspraxis  
 Brückenweg 1  
 D-42929 Wermelskirchen  
 Germany  
 E-mail: gkluxen@t-online.de