
THE ISTENT[®] TRABECULAR MICRO-BYPASS STENT: A CASE SERIES

VANDEWALLE E. *, ZEYEN T. *,
STALMANS I. *

ABSTRACT

Purpose: To evaluate the safety and effectiveness of a trabecular micro-bypass stent, the iStent[™] (Glaukos, USA), for reduction of intraocular pressure in patients with open angle glaucoma.

Methods: In this prospective case series, ten eyes of eight patients underwent a gonioscopically-guided implantation of an iStent[™]. Six eyes underwent combined surgery: cataract surgery followed by iStent[™] implantation, and the remaining four eyes underwent iStent[™] implantation only. The primary outcome measure was intraocular pressure and the secondary outcome measures were the reduction in number of glaucoma medications, and the number of complications.

Results: Mean intraocular pressure dropped from 19.6 mmHg preoperatively to 16.3 mmHg (range 12-27) after one month ($p=0.04$), to 15.4 mmHg (range 8-23) after six months ($p=0.03$) and 15.8 mmHg (range 9-25 mmHg) after one year ($p=0.03$). There was a significant reduction in number of hypotensive medications between baseline and 12 months postoperatively from 2.7 to 1.7 medications. No vision-threatening complications were observed.

Conclusions: The Glaukos[®] iStent trabecular micro-bypass implantation is a safe procedure that is not associated with complications traditionally associated with filtering surgery. This trabecular bypass results in significant mid-term reduction of intraocular pressure as well as the number of medications.

KEY WORDS

glaucoma, intraocular pressure, iStent, trabecular bypass.

.....

* Department of Ophthalmology, University Hospitals
Leuven, Leuven, B-3000, Belgium;

**None of the authors have proprietary interest.
This paper was presented at the OB meeting 2007.**

Submitted:20-01-09; accepted: 08-04-09

INTRODUCTION

Glaucoma is a major cause of blindness in Western countries (1). Intraocular pressure (IOP) is the most significant risk factor for the development of glaucoma as well as its progression (2). Reducing IOP is the only proven treatment modality for reducing the risk of glaucomatous progression and preservation of the visual field. Filtration surgery is the standard procedure for medically uncontrolled glaucoma. Although it has been shown to lower IOP more efficiently than topical medications, it is associated with filtration-bleb related issues in up to 43% of patients within one year postoperatively in the literature (3). The use of adjunctive antimetabolites improves surgical outcome, but also increases the incidence of complications such as hypotony, bleb leaks and endophthalmitis (4-9).

Non-penetrating procedures have been developed as an alternative to traditional filtering surgeries. In deep sclerectomy and viscocanalostomy, the deep sclera and peripheral cornea are excised and Schlemm's canal is unroofed. In the latter procedure, Schlemm's canal is additionally dilated with viscoelastic material. Although these procedures have fewer risks for early postoperative complications than traditional filtering surgery, the utility of these techniques is often limited by their inability to reduce IOP in the low teens, especially for the long term, and by their technical difficulty (10). There is an interest towards minimally traumatic IOP lowering devices that may be used in less advanced glaucoma.

Interest in trabecular bypass is motivated by evidence that the elevated IOP in glaucoma is due to an increased resistance to outflow, and that the majority of resistance is present in the juxtacanalicular connective tissue of the trabecular meshwork (TM) including the inner wall of Schlemm's canal (11-12). In a previous study, an ocular outflow model was developed to investigate the mechanism of action of a trabecular bypass, a patent passageway constructed through the TM into Schlemm's canal (13). In theory, a moderate dilatation of Schlemm's canal and the collector canal in conjunction with a trabecular bypass would reduce the IOP level to the low-to-mid teens (14). An initial case series by Spiegel and Kobuch where six

eyes of five patients underwent an implantation of a trabecular bypass tube shunt, showed promising results (15). In cultured human anterior segments, a single bypass of TM indeed lowered IOP from 21.4 ± 3.8 mm Hg to 12.4 ± 4.2 mm Hg ($p < 0.001$). The sequential addition of more stents further lowered pressure in seven of the nine eyes studied (16).

The Glaukos® iStent® trabecular micro-bypass (Glaukos Corporation, Laguna Hills, California, USA) is made of surgical grade titanium with a heparin coating and measures $0.5 \times 0.25 \times 1$ mm. This prospective study was undertaken to investigate the safety and efficacy of this novel drainage device.

MATERIALS AND METHODS

DESIGN

This was a prospective 12-month clinical evaluation of the efficacy and safety of the Glaukos® iStent® in eight patients with open angle glaucoma whose IOP was insufficiently controlled by their current ocular hypotensive medication(s).

PATIENTS

Inclusion criteria included open angle or pseudoexfoliation glaucoma as determined by the presence of typical optic nerve and visual field damage, with IOP above the target pressure and despite maximum tolerated medical therapy. The target pressure was defined using a previously published formula. Target IOP = Maximum IOP - Maximum IOP% - Z, where Z is an optic nerve damage severity factor (17-18). No washout of the patient's ocular hypotensive medications was required.

Exclusion criteria included best-corrected visual acuity less than 20/200 in either eye, conditions interfering with reliable Goldmann applanation tonometry, peripheral anterior synechia or insufficient gonioscopic visualisation of the trabeculum, and elevated episcleral venous pressure.

This study was conducted in accordance with the tenets of the World Medical Association Declaration of Helsinki and an informed consent was obtained from all subjects after the

experimental nature of the procedure had been fully explained.

OBSERVATION PROCEDURE

A complete ophthalmological examination was performed before surgery. Preoperative assessment included visual acuity evaluation, Goldmann applanation tonometry measurement, slit lamp biomicroscopy, 90 D ophthalmoscopy, automated perimetry and gonioscopy.

SURGICAL TECHNIQUE

Retrolbulbar anaesthesia was used in all cases. A 1.5 mm clear corneal incision was made temporally on the horizontal axis if the procedure was not combined with cataract surgery. In the patients that underwent combined surgery, the clear corneal cataract incision was used. The anterior chamber was filled with Viscoat® (Alcon, Puurs, Belgium). The inserter with the mounted Glaukos® iStent® was introduced into the anterior chamber, and subsequently the trabeculum was visualized using a direct gonioscopy and tilting of the microscope. The iStent® was advanced towards the identified implantation site, which was in the inferonasal quadrant, inserted into the TM at a slight angle, and advanced into Schlemm’s canal until the proximal aperture touched the TM. The iStent® was seated by gently tapping the side of the proximal aperture. The stent was released from the inserter, which was withdrawn, and viscoelastic was carefully removed. The incision was closed by hydration, and in cases of a persistent Seidel phenomenon a Nylon 10-0 suture was placed. Before ending the procedure, a final confirmation of the correct iStent® position was performed using the gonioscopy.

FOLLOW-UP EVALUATIONS

Patients discontinued their IOP-lowering medications immediately after the procedure and were instructed to resume treatment only if the investigator determined that additional IOP-lowering was needed.

Patients were evaluated on postoperative day 1, after 1 and 2 weeks, and at 1, 3, 6 and 12 months. Postoperative assessment included visual acuity evaluation, applanation tonometry measurement, biomicroscopy and ophthalmos-

copy. Stent location and condition were evaluated gonioscopically. Adverse events and number of glaucoma medications were documented.

OUTCOME MEASURES AND STATISTICAL ANALYSES:

The primary outcome measure was IOP as determined by Goldmann applanation tonometry. The second outcome measure was the number of glaucoma medications pre- and post-operatively. A paired t-test and a Wilcoxon test were used for the IOP and medication analysis. Failure was considered if the patient needed subsequent filtering surgery. Results were considered significant when $p < 0.05$.

RESULTS

PATIENT CHARACTERISTICS (TABLE 1)

Ten eyes from eight patients were included in the study. Six eyes (60%) underwent combined surgery (cataract surgery followed by iStent® implantation), and the remaining four eyes (40%)

Table 1: Baseline characteristics of the patients in this study.

Baseline characteristics	Mean (Range)
Age (years)	69 (50-81)
Preoperative IOP (mmHg)	20 (13-28)
Number of preoperative medications	2.7 (1-4)
Visual acuity (log Mar)	0.4 (0.05-2)
Mean Deviation	-13.7 (-1.8 ~ -27.9)
Type of glaucoma	Number (%)
Primary open angle	7 (70)
Pseudo exfoliation glaucoma	3 (30)
Antecedents	Number (%)
Negative	3 (30)
Phacoemulsification	2 (20)
Nd:YAG laser iridotomy	2 (20)
Laser trabeculoplasty	4 (40)
Trabeculectomy	1 (10)
LASIK	1 (10)
Laser for retinal detachment	1 (10)

IOP: intraocular pressure, log Mar: logarithm of the mean angle of resolution, ND:YAG: Neodymium: Yttrium Aluminium Garnet, LASIK: Laser assisted in-situ keratectomy.

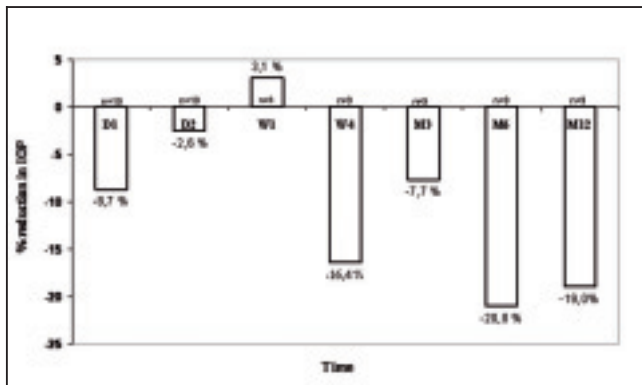


Fig. 1: Percent Reduction in IOP from Baseline.

IOP: intraocular pressure, D: day, W: week and M: Month.

underwent iStent[®] implantation only. Table I summarizes the patients' baseline characteristics, diagnosis and past ocular history.

MEAN IOP AT EACH STUDY VISIT (FIGURES 1 AND 2)

Overall, mean IOP dropped from 19.6 mmHg (range 13-28 mm Hg) preoperatively to 16.3 mmHg (range 12-27) after one month ($p=0.04$), 15.4 mmHg (range 8-23) after six months ($p=0.03$) and 15.8 mmHg (range 9-25 mm Hg) after one year ($p=0.03$). This represents a reduction in IOP from baseline of 16.4% at one month, 20.8% at six months and 19.0% at one year (Figure 1). At one year, 7 of the 9 eyes had an IOP below their target pressure. For more than half of the included eyes, the target pressure was below 18 mmHg. For four eyes, the target pressure was lower (below 17 mmHg for eye 4 and 5 and below 15 mmHg for eyes 8 and 9).

In eyes two and ten, high pressures (31 mmHg and 40 mmHg, respectively) were observed the day after surgery. In one of them (eye 2), this pressure elevation was presumably due to inflammation and excessive reflux of blood, and the pressure spontaneously lowered as the inflammation resolved and as the red blood cells were washed out. In the other (eye 10), the pressure remained high postoperatively. Of note, in this patient excessive blood reflux was observed immediately following iStent[®] implantation, which was peroperatively washed out by

manual irrigation. Slit lamp examination performed on the next day revealed no significant inflammation. Gonioscopy confirmed correct position of the iStent[®] and blood remnants in the anterior chamber angle. Pressures remained high (27 mmHg) despite the instillation of maximal medical therapy, and a trabeculectomy was performed after one month. Three additional patients had pressures above 21 mmHg, two of which after one week (eyes 3 and 7) and one at three months postoperatively (eye 6), but responded well to re-initiation of topical therapy. In another five patients, (eyes 1, 4, 5, 8 and 9), topical therapy was started again despite pressures below 21 mmHg because the IOP values were above the target pressure at various time points (Figure 2).

NUMBER OF OCULAR HYPOTENSIVE MEDICATIONS

The mean number of topical ocular medications dropped from 2.7 (range 1-4) preoperatively to 1.7 (range 0-3) after one year ($p<0.01$). The subgroups were too small to perform relevant statistical analyses on the reduction of medications in the iStent[®] only *versus* combined surgery groups.

PROCEDURE AND COMPLICATIONS

The procedures were performed between January 2006 and March 2007. There were eight right eyes and two left eyes. Nine eyes had a successful iStent[®] implantation after the first attempt and only one eye received a second stent in the same session because the position of the first stent was doubtful (eye 5).

There were no major complications in this case series. In the patients that underwent iStent[®] implantation only, visual acuity remained stable, and after combined surgery visual acuity improved. Two eyes had a corneal erosion postoperatively, presumably due to the repeated preoperative gonioscopies, which healed within two days. Reflux of blood through the stent into the angle following implantation occurred in five eyes (four of which underwent combined surgery), resolving within a few days.

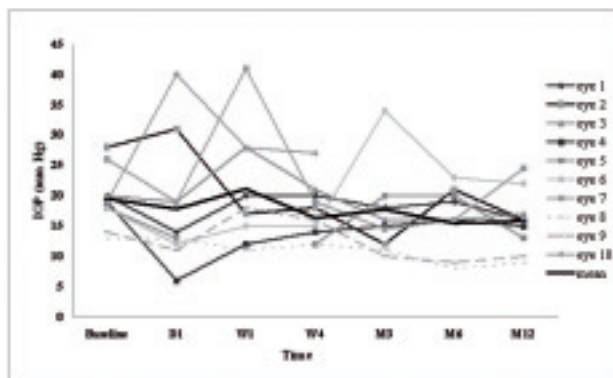


Fig. 2: Mean IOP at Each Study Visit.

IOP: intraocular pressure, D: day, W: week, M: month, eye: combined procedure: phaco followed by iStent™ implantation and eye: iStent™ implantation alone.

DISCUSSION

Glaucoma is a major cause of irreversible blindness in both the developed and developing world, accounting for 15% of all blindness and over 500,000 new cases each year (19-20). The treatment of this disease is directed towards the reduction of IOP, the main identifiable risk factor in glaucoma. Of all available therapies, filtering surgery has been shown to be the most effective for achieving lower IOPs (21) and preventing progressive vision loss (22). However, conventional filtering surgery (trabeculectomy) can be associated with considerable complications including early complications (e.g., bleb leak, excessive filtration, flat anterior chamber, filtration failure) as well as late complications (e.g., bleb leak, excessive filtration and hypotony, symptomatic blebs, bleb encapsulation, filtration failure, bleb infection) (23). Moreover, it is not always successful due to the occurrence of excessive post-operative scarring (24). The introduction of peroperative anti-proliferative anti-scarring agents, such as mitomycin-C or 5-Fluorouracyl, has been shown to improve surgical outcome (25). One must note, however, that the antimetabolites, especially mitomycin-C, do carry a substantial risk of vision-threatening complications such as persistent hypotony, leaking blebs, blebitis, endophthalmitis and scleral melting (4-9).

To further improve the surgical approach of glaucoma, extensive efforts have been made to

develop safe alternatives as Trabectome™, iStent®, iScience (canaloplasty) and Solx (suprachoroidal shunt) (26).

The TM is the primary site for increased resistance to aqueous outflow in open angle glaucoma (27). The iStent®, a trabecular bypass microstent, is designed to create a patent TM bypass and restore fully developed physiologic outflow in glaucoma patients. The *ab-interno* implant procedure spares the conjunctiva and preserves all future surgical and drug options. This microstent implant can reduce resistance attributable to the meshwork and provide an increase in outflow facility from $0.12 \pm 0.032 \mu\text{l}/\text{min}/\text{mmHg}$ preoperatively to $0.79 \pm$

$0.53 \mu\text{l}/\text{min}/\text{mmHg}$ after six months ($p < 0.001$) (28). An earlier design of a trabecular microshunt has been reported by Spiegel et al (15). However, this larger and more flexible prototype was designed to be inserted *ab externo*, and thus required dissection of the conjunctiva. This is a major disadvantage because it compromises further filtering surgery and does not prevent bleb-related complications. Moreover, it is more laborious, time-consuming and technically more challenging than the iStent® implantation.

We report on the 1-year results after implantation of the iStent® in a series of ten eyes. In our series, we did not observe any major complication of this technique. Four out of six eyes that underwent combined surgery and one eye that underwent iStent® implantation only showed reflux of blood through the stent following implantation, whereas this occurred in only one eye that underwent stent implantation alone. This observation is most probably related to the fact that at the end of cataract surgery, Schlemm's canal is filled with blood, which can subsequently easily leak through the stent into the anterior chamber once it is inserted.

A mean reduction of 3.2 mmHg (16.4%) at one month, 4.1 mmHg (20.8%) at six months and 3.7 mmHg (19.0%) after one year was observed. These results are comparable to a previous small series of 6 patients (29). At one year 7 of the 9 eyes were under their target pressure. The target pressure is the upper lim-

it IOP that is thought to prevent further glaucomatous damage in a particular patient. Several algorithms have been published. We used the one that was defined by H. Jampel (17) and slightly modified by T. Zeyen (18). For more than half of the included eyes, the target pressure was below 18 mmHg. For four eyes, the target pressure was lower (below 17 mmHg for eye 4 and 5 and below 15 mmHg for eyes 8 and 9). From these observations, we conclude that iStent[®] implantation may be suitable for patients with a target pressure in the mid- or higher teens, but may be less suitable for patients with a very low target IOP, such as in patients with normal tension glaucoma.

Additional to the IOP lowering effect, a significant decrease in the number of ocular medications was observed ($p < 0.001$). It is noteworthy that, despite an IOP drop of almost ten percent the first day postoperatively, no significant IOP lowering was observed after one week, but a significant IOP drop was observed thereafter. Since postoperative inflammation was only mild, this observation can rather be explained by the fact that all medications were discontinued or tempered after surgery, such that the patients were off all medications after 1 week, and medications were then gradually reinstalled when judged necessary.

We registered one failure, who underwent a trabeculectomy one month after iStent[®] implantation. This case had previously undergone LASIK surgery. He exhibited pronounced blood reflux through the stent during surgery. The relationship between these observations and the uncontrolled IOP is unclear.

Of note, the IOP-lowering was more pronounced in the combined surgery as compared to the iStent[®] implantation only. Cataract surgery has been shown to have an IOP-lowering effect, albeit to a lesser extent than in our small series of combined surgery. Park *et al.* reported a mean IOP reduction of 1.2 mmHg at 12 months after phaco-emulsification (30). The reduction in IOP observed in our six patients that underwent combined surgery was 5.2 mmHg (27.2%) at 12 months, which is greater than IOP reduction previously reported from cataract surgery alone. Furthermore, combining cataract surgery an iStent implantation leaves the conjunctiva untouched, which is of potential ben-

efit in cases needing additional filtering surgery.

In summary, the iStent[®] offers a novel approach to filtering surgery. To the best of our knowledge, this is only the second paper on clinical results of iStent[®] implantation, and the second paper reporting on results of combined phaco-emulsification and iStent[®] implantation. While these initial results are promising, additional studies with longer follow-up and larger groups are required in order to confirm the safety and the ocular hypotensive efficacy of this technique. Moreover, further studies are mandatory to further explore the additive IOP-lowering effect of iStent[®] implantation to phaco-emulsification. The preliminary analysis of treatment by cataract surgery and the iStent[®] trabecular micro-bypass stent by Spiegel have shown promising results for a new surgical approach to provide clinically significant decreases in IOP and drug burden (31).

REFERENCES

- (1) LESKE M.C. – The epidemiology of open-angle glaucoma: a review. *Am J Epidemiol* 1983; 118: 166-191.
- (2) LANDERS J., GOLDBERG I., GRAHAM S.L. – Analysis of risk factors that may be associated with progression from ocular hypertension to primary open-angle glaucoma. *Clin Exp Ophthalmol* 2002; 30: 242-247.
- (3) JANZ N.K., WREN P.A., LICHTER P.R. et al. – The collaborative initial Glaucoma Treatment study: interim quality of life findings after initial medical or surgical treatment of glaucoma. *Ophthalmology* 2001; 108: 1954-1965.
- (4) HIGGINBOTHAM E.J., STEVENS R.K., MUSCH D.C. et al. – Bleb-related endophthalmitis after trabeculectomy with mitomycin C. *Ophthalmology* 1996; 103: 650-656.
- (5) SOLTAU J.B., ROTHMAN R.F., BUDENZ D.L. et al. – Risk factors for glaucoma filtering bleb infections. *Arch Ophthalmol* 2000; 118: 338-342.
- (6) PARRISCH R., MINCKLER D. – Late endophthalmitis-filtering surgery time bomb? *Ophthalmology* 1996; 103: 1167-1168.
- (7) GREENFIELD D.S., SUNER I.J., MILER M.P., KANGAS T.A., PALMBERG P.F., FLYNN H.W. – Endophthalmitis after filtering surgery with mitomycin. *Arch Ophthalmol* 1996; 114: 943-949.
- (8) STAMPER R.L., MCMENEMY M.G., LIEBERMAN M.F. – Hypotonous maculopathy after

- trabeculectomy with subconjunctival 5-fluorouracil. *Am J Ophthalmol* 1992; 114: 544-553.
- (9) JAMPÉL H.D., PASQUALE L.R., DIBERNARDO C. – Hypotony maculopathy following trabeculectomy with mitomycin C. *Arch Ophthalmol* 1992; 110: 1049-1050.
 - (10) HONDUR A., ONOL M., HASANREISOGLU B. – Nonpenetrating Glaucoma surgery: Meta-Analysis of Recent Results. *J Glaucoma* 2008;17:139-146.
 - (11) GRANT W.M. – Experimental aqueous perfusion in enucleated human eyes. *Arch Ophthalmol* 1963; 69: 738-801.
 - (12) JOHNSON D.H., JOHNSON M. – How does nonpenetrating glaucoma surgery work? Aqueous outflow pathway morphology. *Invest Ophthalmol Vis Sci* 1999; 40: 1676-1680.
 - (13) ZHOU J., SMEDLEY G.T. – A trabecular bypass flow hypothesis. *J Glaucoma* 2005; 14: 74-83.
 - (14) ZHOU J., SMEDLEY G.T. – Trabecular bypass: effect of Schlemm canal and collector canal dilatation. *J Glaucoma* 2006; 15: 446-455.
 - (15) SPIEGEL D., KOBUCH K. – Trabecular meshwork bypass tube shunt: initial case series. *Br J Ophthalmol* 2002; 86: 1228-1231.
 - (16) BÄHLER C.K., SMEDLEY G.T., ZHOU J., JOHNSON D.H. – Trabecular bypass stents decrease intraocular pressure in cultured human anterior segments. *Am J Ophthalmol* 2004; 138: 988-994.
 - (17) JAMPÉL H.D. – Target pressure in glaucoma therapy. *J Glaucoma* 1997; 6: 133-138.
 - (18) ZEYEN T. – Target pressures in glaucoma. *Bull Soc belge Ophthalmol* 1999; 274: 61-65
 - (19) THYLEFORS B., NEGREL A.D. – The global impact of glaucoma. *Bull World Health Organ* 1994; 72: 323-326.
 - (20) FOSTER A., JOHNSON G.J. – Magnitude and causes of blindness in the developing world. *Int Ophthalmol* 1990; 14: 135-140.
 - (21) MIGDAL C., GREGORY W., HITCHINGS R. – Long-term functional outcome after early surgery compared with laser and medicine in open-angle glaucoma. *Ophthalmology* 1994; 101: 1651-1656; discussion 1657.
 - (22) The AGIS Investigators. The Advanced Glaucoma Intervention Study (AGIS): 7. The relationship between control of intraocular pressure and visual field deterioration. *Am J Ophthalmol* 2000; 130: 429-440.
 - (23) AZUARA-BLANCO A., KATZ L.J. – Dysfunctional filtering bleb. *Surv of Ophthalmol* 1998; 2: 93-126.
 - (24) ADDICKS E.M., QUIGLEY H.A., GREEN W.R., ROBIN AL. – Histologic characteristics of filtering blebs in glaucomatous eyes. *Arch Ophthalmol* 1983; 101: 795-798.
 - (25) YOON P.S., SINGH K. – Update on antifibrotic use in glaucoma surgery, including use in trabeculectomy and glaucoma drainage implants and combined cataract and glaucoma surgery. *Curr Opin Ophthalmol* 2004; 15: 141-146.
 - (26) MINCKLER D.S., RICHARD A.H. – Use of novel devices for control of intraocular pressure. *Exp eye res* 2009; doi:10.1016/j.exer.2008.11.010.
 - (27) JOHNSON D.H., JOHNSON M. – How does nonpenetrating glaucoma surgery work? Aqueous outflow resistance and glaucoma surgery. *J. Glaucoma* 2001; 10:55-67.
 - (28) FDEZ-BARRIENTOS Y., MARTÍNEZ-DE-LA-CASA J.M., GARCÍA-FEIJÓO J. et al. – Fluorophotometric study of the effect of cataract surgery and trabecular microbypass on aqueous humour dynamics: preliminary results. Poster at Hospital Clinico San Carlos. Instituto Castroviejo, Universidad Complutense, Madrid, Spain.
 - (29) SPIEGEL D., WETZEL W., HÄFFNER D.S., HILL R.A. – Initial clinical experience with the trabecular micro-bypass stent in patients with glaucoma. *Adv Ther* 2007; 24: 161-170.
 - (30) PARK M., TANITO M., NISHIKAWA M., HAYASHI K., CHICHARA E. – Combined visco-canalostomy and cataract surgery compared with cataract surgery in Japanese patients with glaucoma. *J of Glaucoma* 2004; 13: 55-61.
 - (31) SPIEGEL D., GARCÍA-FEIJÓO J., GARCÍA-SÁNCHEZ J., LAMIELLE H. – Coexistent primary open-angle glaucoma and cataract: preliminary analysis of treatment by cataract surgery and the iStent trabecular micro-bypass stent. *Adv Ther* 2008; 25:453-464.

ACKNOWLEDGEMENTS

The authors would like to thank Lidwine Van Malderen (Ir, University Hospitals Leuven, Leuven) for her assistance with the statistical analyses of the study data.

.....

Correspondence and reprints

Prof. Dr Ingeborg Stalmans
 Department of Ophthalmology
 University Hospitals Leuven, Campus St Raphaël
 Kapucijnenvoer, 33
 B-3000 Leuven, Belgium
 e-mail: ingeborg.stalmans@uz.kuleuven.be